

## Case Report

# Neonatal Immature Gastric Teratoma: Pathophysiology and Treatment Outcomes

Ahmed H. Al-Salem

Department of Pediatric Surgery, Maternity and Children Hospital, Dammam, Saudi Arabia.  
E-mail: [ahsalsalem@hotmail.com](mailto:ahsalsalem@hotmail.com).

Accepted 25 October, 2020

**Gastric teratomas are very rare embryonal neoplasms and accounts for less than 1% of all teratomas occurring in infants and children. It is usually seen in male infants who present with upper abdominal mass and commonly it is benign. This report describes a large immature grade II gastric teratoma in a male newborn. The tumor was treated with total excision including part of the stomach.**

**Key words:** Gastric teratoma, newborn, immature.

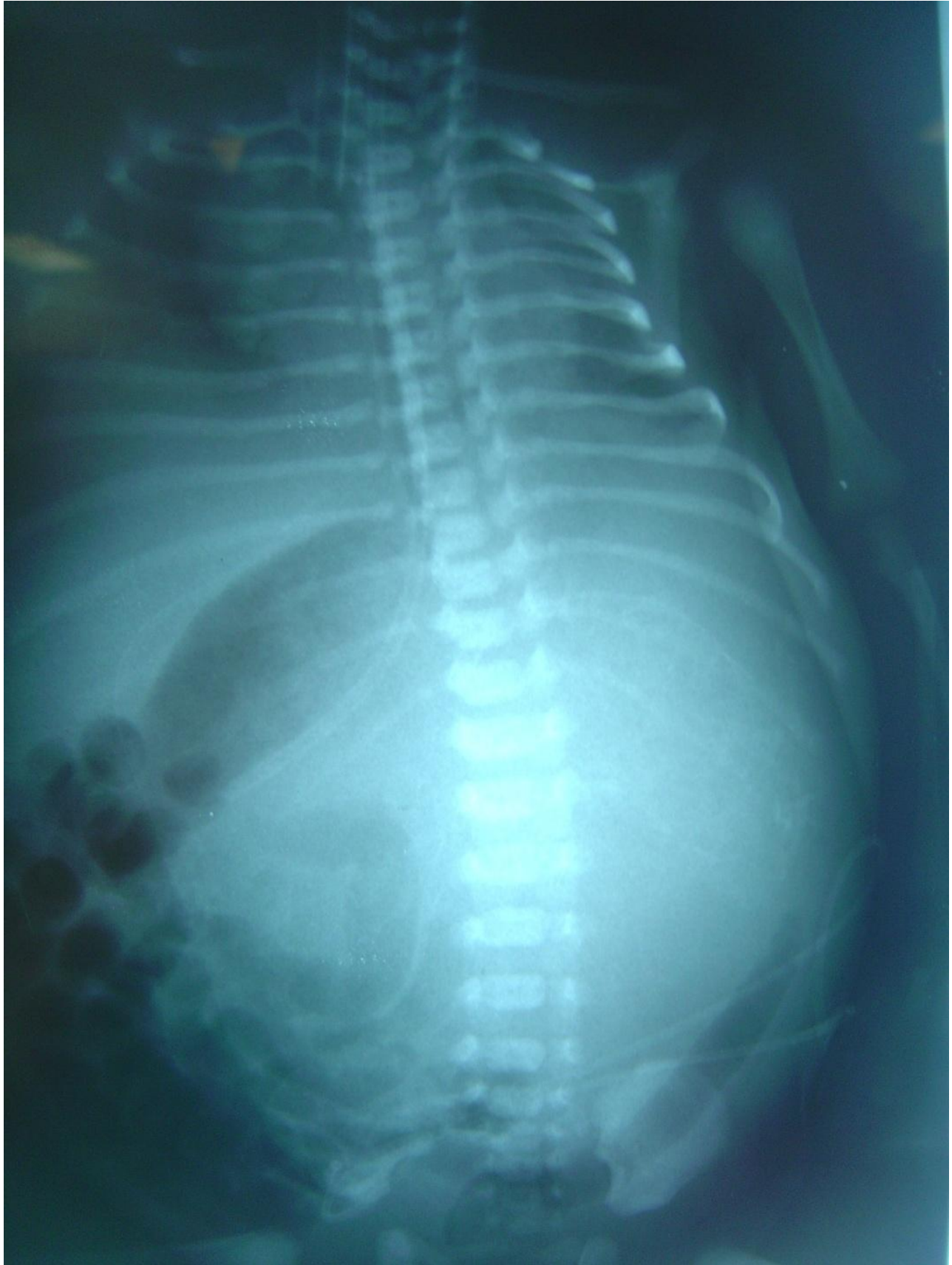
## INTRODUCTION

Teratomas are relatively common embryonal tumors that arise from totipotent cells and usually contain elements from all the three germ layers, ectoderm, endoderm and mesoderm (Grosfeld et al., 1976). Commonly, they are seen in the ovary, testes, sacrococcygeal area and retroperitoneal space and they can be benign or malignant (Grosfeld et al., 1976; Berry et al., 1969). Gastric teratomas on the other hand are very rare, usually seen in male infants and usually present with a palpable upper abdominal mass that can attain a large size. The histopathology confirms the diagnosis and specifies the maturity of the teratoma. A grading system, based on histopathological findings, divides the gastric teratoma in two main types, mature teratoma (grade 0) and immature teratoma (grades 1, 2, 3). Mature teratoma is characterized by well differentiated tissues from all the three germinal layers. Immature teratoma on the other hand is characterized by the presence of immature neuroectodermal tissue along with other germinal layers structures. Immature teratoma is divided into three grades. In grade 1, the immature neuroectodermal tissue is confined to one site in a slide, whereas in grades 2 and 3, the immature tissue is found in less than 4 and more than 4 fields per slide, respectively. Most of the gastric teratomas are considered to be benign but there are reports of malignant gastric teratoma and malignant gastric teratomas have also been reported (Gupta et al., 2000; Sharma et al., 1994; Matias and Huang, 1973; Gore and Fernbach, 2002; Bourke et al., 1997; Balik et al., 1990; Curtis et al., 2008, Saha, 2010). The recom-

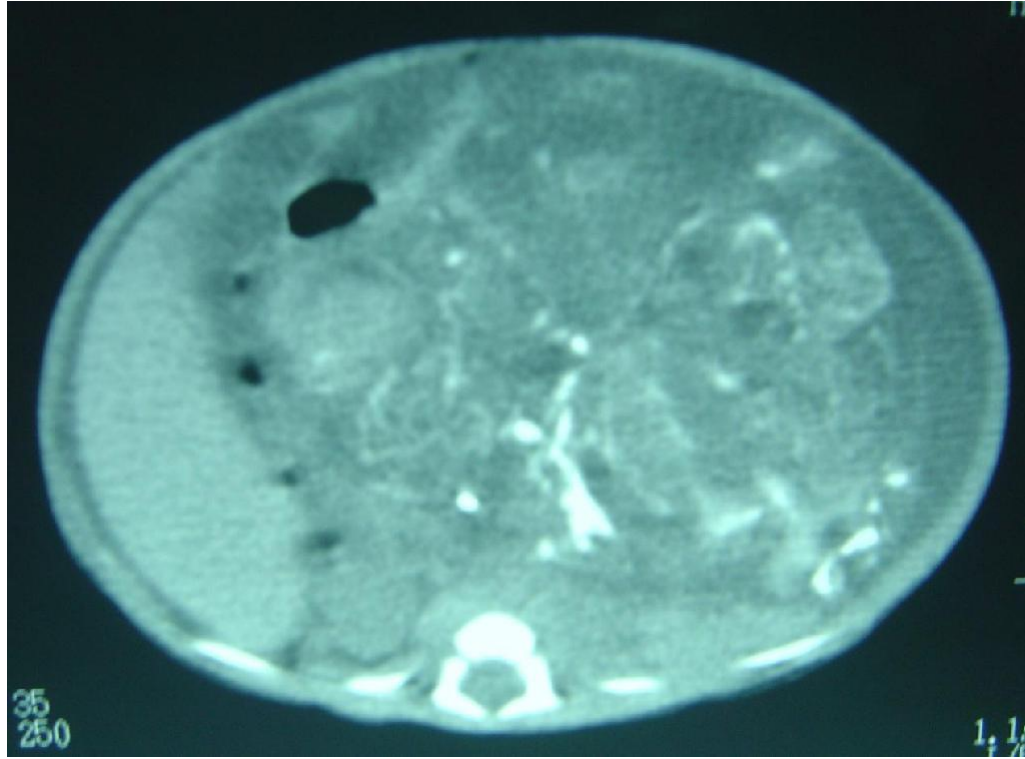
mended therapy for gastric teratomas is total surgical excision. This report describes a large immature grade 2 gastric teratoma in a male newborn.

## CASE REPORT

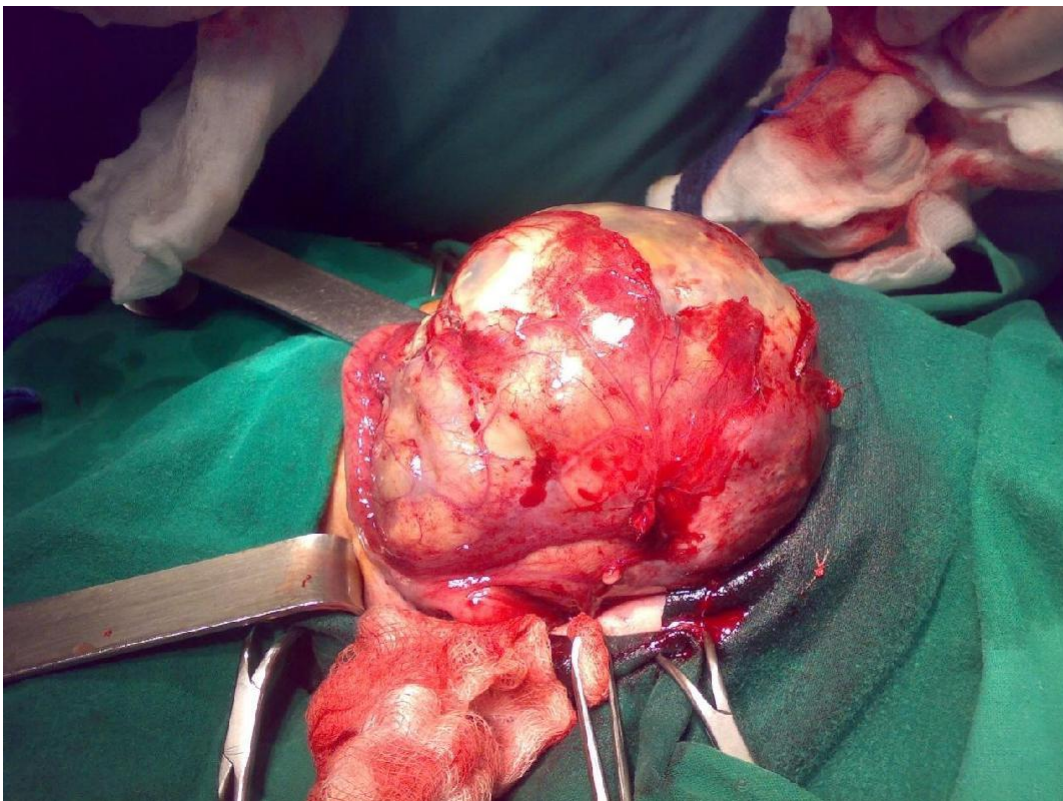
A 3-day-old male newborn, a product of full term normal vaginal delivery to a gravida 5 para 3+1 mother was referred to our hospital with an abdominal mass. Immediately after birth, he was noticed to have a large abdominal mass. Two days later, he developed respiratory distress and was intubated and ventilated. Abdominal x-ray showed a large soft tissue mass with calcification occupying most of the abdominal cavity and displacing the bowel to the right side (Figure 1). Abdominal ultrasound showed a normal right kidney. The left kidney was also normal but displaced inferoposteriorly. There was a large poorly demarcated heterogenous mass occupying most of the abdominal cavity with mild ascites. This was confirmed with an abdominal CT-scan (Figure 2). The alpha fetoprotein was more than 10,000 i.u and beta-HCG was normal. He underwent an exploration laparotomy and was found to have a large abdominal tumor occupying most of the abdominal cavity and arising from the posterior wall of the stomach (Figure 3). The whole tumor and part of the stomach wall was excised (Figure 4). Histology of the resected tumor showed a grade 2 immature teratoma. A minor component of yolk sac tumor could not be excluded. Post-operatively, he did well and was discharged home on the 14<sup>th</sup> postoperative day. Prior to discharge, the alpha fetoprotein level was 859.5 i.u. On follow up, he was thriving well and two months following



**Figure 1.** Plain abdominal X-ray showing a large soft tissue mass with calcifications and displacing the bowels.

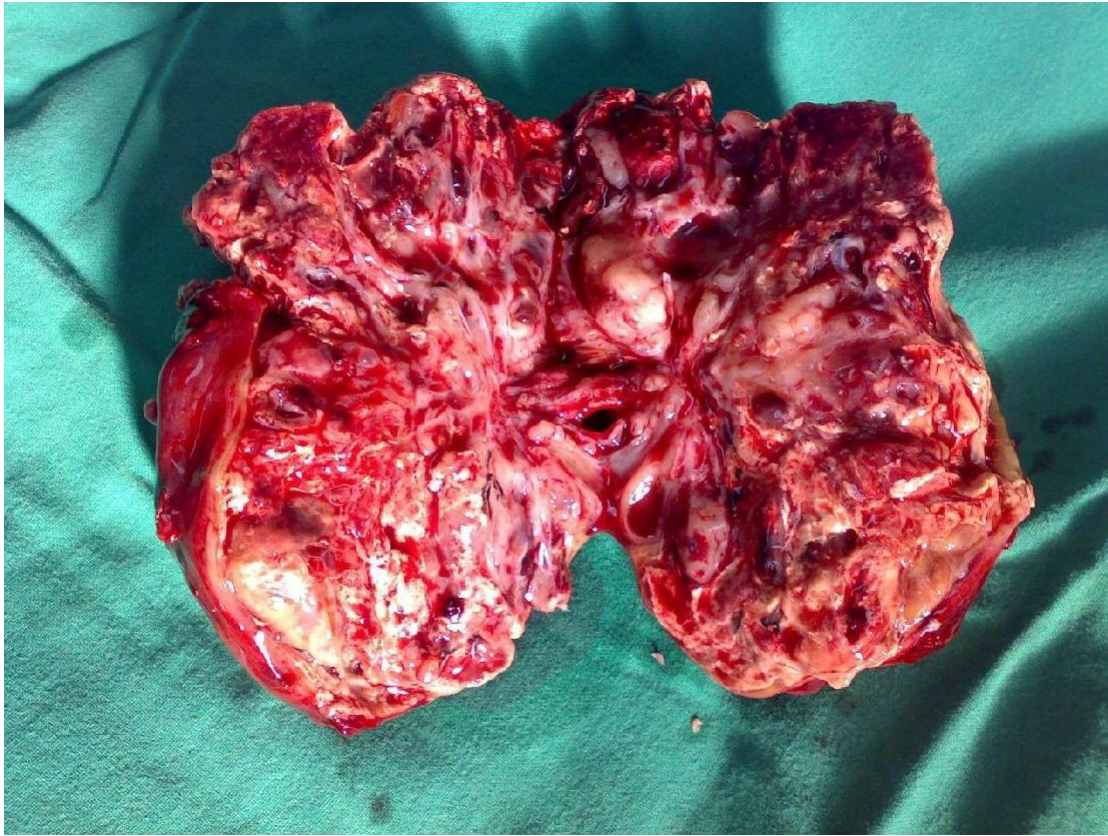


**Figure 2.** CT-scan of the abdomen showing a large abdominal mass with calcifications occupying most of the abdominal cavity.



**Figure 3.** Clinical photograph showing a large abdominal tumor.





**Figure 4.** Clinical photograph showing the resected gastric tumor.

discharge, the alpha fetoprotein fell to 325.2 i.u., and a month later, it was 170.3 i.u. He is now 1.5 years post-operative, doing well with no clinical or radiological evidence of recurrence and a normal alpha fetoprotein.

## **DISCUSSION**

Primary gastric tumors are very rare in infants and children. Over a period of 54 years, Curtis et al. (2008) reported 21 infants and children with primary gastric tumors, 4 of them only had gastric teratoma. Gastric teratomas are very rare, accounting for less than 1% of all teratomas in infants and children (Grosfeld et al., 1976). For unknown reasons, there is a male preponderance with 90% of cases reported in boys and mostly seen in infants (Gupta et al., 2000; Sharma et al., 1994; Matias and Huang, 1973; Gore and Fernbach, 2002; Wildbrett et al., 2012; Sharma et al., 2010). Clinically, the majority present with abdominal distension and a palpable abdominal mass, but there are reports of gastric teratomas presenting with upper gastrointestinal bleeding (Shadi et al., 1996; Hirugade et al., 2001; Haley et al., 1986). This is seen in cases of gastric teratoma with intraluminal growth of the tumor and mucosal ulceration.

These tumors can also attain a large size and may cause respiratory difficulty due to displacement of the diaphragm, premature labour or dystocia (Matias and Huang, 1973). Spontaneous rupture and perforation of large gastric teratoma has also been reported (Haley et al., 1986; Park et al., 2002, Bakunai and Ochida, 1960).

The management of gastric teratoma is surgical excision of the tumor and part of its attachment to the stomach. This is usually curative and rarely partial or total gastrectomy is necessary depending on the extent of the tumor (De Angelis, 1969). The majority of gastric teratomas however are benign and in the presence of immature neuroepithelium tissue, these tumors are considered malignant, but even then, the prognosis is excellent after total excision. Gupta et al. (2000) in a review of 10 cases of gastric teratomas reported 2 patients with immature grade 3 gastric teratoma, one of them infiltrated the left lobe of the liver and the transverse colon, while the other had metastasized to the regional lymph nodes and omentum but in spite of this and following complete excision, there was no recurrence after a mean follow-up of 4.2 years without chemo or radio therapy. Our patient had a large grade 2 immature gastric teratoma and following total excision, there was no evidence of recurrence after a follow-up of 1.5 years

without chemotherapy or radiotherapy. Bourke et al. (1997) reported a malignant gastric teratoma in a 4-month-old male child that was totally excised and was well after 12-month follow-up. Balik et al. (1990) reported the second case of malignant gastric teratoma in an infant that was also treated by total excision. Ukiyama et al. (2005) on the other hand reported a recurrent yolk sac tumor following resection of a neonatal immature gastric teratoma. This calls for a close follow-up of all patients with immature gastric teratoma. Serum alpha fetoprotein is a useful marker in these patients for evidence of recurrence or the presence of residual tumor.

## Conclusion

In conclusion, gastric teratoma is rare and must be considered in the differential diagnosis of abdominal tumors in newborns. The majority of gastric teratomas are benign, and total surgical excision is curative even in malignant cases. A close follow-up is however mandatory for those with immature teratoma.

## REFERENCES

- Bakunai S, Ochida H (1960). A case report of large gastric teratoma with perforation. *Tokyo Med.*, 77: 373-374.
- Balik E, Tunçyürek M, Sayan A, Avanoğlu A, Ulman I, Cetinkurşun S (1990). Malignant gastric teratoma in an infant. *Z Kinderchir*, 45:383-5.
- Berry CL, Keeling J, Hilton C (1969). Teratoma in infancy and childhood: a review of 91 cases. *J. Pathol.*, 98: 241-252.
- Bourke CJ, Mackay AJ, Payton D (1997). Malignant gastric teratoma: case report. *Pediatr. Surg. Int.*, 12:192-3.
- Curtis JL, Burns RC, Wang L, Mahour GH, Ford HR (2008): Primary gastric tumors of infancy and childhood: 54-year experience at a single institution. *J. Pediatr. Surg.*, 43:1487-1493.
- De Angelis VR (1969). Gastric teratoma in a newborn infant: total gastrectomy with survival. *Surgery*, 66(4): 794-797.
- Gore MD, Fernbach SK (2002). Gastric teratoma. *Radiology*, 225: 497-499.
- Grosfeld JL, Ballantine TV, Lowe D, Baeleur RL (1976). Benign and malignant teratomas in children. Analysis of 85 patients. *Surgery*, 80: 297-307.
- Gupta DK, Srinivas M, Dave S, Agarwala S, Bajpai M, Mitra DK (2000). Gastric teratoma in children. *Pediatr. Surg. Int.*, 16: 329-323.
- Haley T, Dimler M, Hollier P (1986). Gastric teratoma with gastrointestinal bleeding. *J. Pediatr. Surg.*, 21(11): 949-950.
- Hirugade ST, Deshpande AV, Talpallikar MC, Borwankar SS (2001). Gastric teratoma: a rare cause of gastrointestinal bleeding. *Indian J. Gastroenterol.*, 20(4):158-159.
- Matias IC, Huang YC (1973). Gastric teratoma in infancy: Report of a case and review of world literature. *Ann. Surg.*, 178:631-636.
- Park WH, Choi So, Kim JI (2002). Congenital gastric teratoma with gastric perforation mimicking meconium peritonitis. *J. Pediatr. Surg.*, 1(4): 226-228.
- Saha M (2010). Malignant gastric teratoma: report of two cases from a single center. *Pediatr. Surg. Int. Sep*; 26(9): 931-4.
- Shadi SM, Hassab MH, El-Magid AA, Abdalla AS, Al-Olayat YF, Al-Bassam AA (1996). *Annals Saudi Med.*, 16:677-678.
- Sharma A, Arora R, Gupta R, Dinda AK (2010). Immature gastric teratoma in an infant: report of a case and review of the literature. *Indian J. Pathol. Microbiol.*, 53(4): 868-70.
- Sharma AK, Sarin YK, Agarwal LD (1994). Immature gastric teratoma in a neonate. *Indian Pediatr.*, 31:357-360.
- Ukiyama E, Endo M, Yoshida F (2005). Recurrent yolk sac tumor following resection of a neonatal immature gastric teratoma. *Pediatr. Surg. Int.*, 21(7): 585-588.
- Wildbrett P, Einsiedel HG, Lange B, Lode H, Barthlen W (2012). Gastric teratoma in a 6-month-old boy. *Afr. J. Paediatr. Surg.*, 9(1): 71-3.