

*Full Length Research Paper*

# An experimental study of the best methods of duodenal repair

**\*Sachin M. Khan, Shankar K. Ranvid and Gupta H. Singh**

Department of Urology and Surgery, Faculty of Medicine, University of Delhi, New Delhi, India.

Accepted 15 March 2015

Duodenal injuries are rare and complete circumferential duodenal injuries are rarest to encounter. The best method of their repair is still an enigma. This article and experimental study aimed to elucidate the best methods of duodenal repair. We encountered few duodenal injuries which began from February 2011 – the first one with duodenal injury involving the first part of duodenum posteriorly. Another duodenal injury was complete circumferential involving first and third parts of duodenum, along with laceration of superior mesenteric artery. Only one case of double duodenal transection has been reported in world literature, and that associated with superior mesenteric artery laceration has not been reported. In one case of double duodenal transection, we attempted a novel technique for managing double complete circumferential duodenal injury by using a 16 fr stenting gastroduodenojejunal catheter. Both injuries were repaired primarily and had good postoperative outcome. Duodenal injuries should not be feared. Meticulous and judicious repair of duodenal injuries brings good results.

**Key words:** Traumatic duodenal injuries, Iatrogenic duodenal injuries, double duodenal transection, stenting gastroduodenojejunal catheter.

## INTRODUCTION

Duodenal injuries are rarely presented in clinical practice. Double duodenal transections are rarest and double duodenal transection with superior mesenteric artery laceration has not yet been reported in world literature. Only reported case of double duodenal transection in world literature has been reported. Zelic et al. (2010) reported a case of 20-year-old male with isolated complete duodenal transection at two duodenal segments after blunt abdominal trauma. Although there is no reported case of double duodenal transection, associated superior mesenteric artery laceration with these injuries was first reported with successful outcome of repair. Various techniques have been described to manage these injuries. We devised a novel technique to manage double duodenal transection, with successful

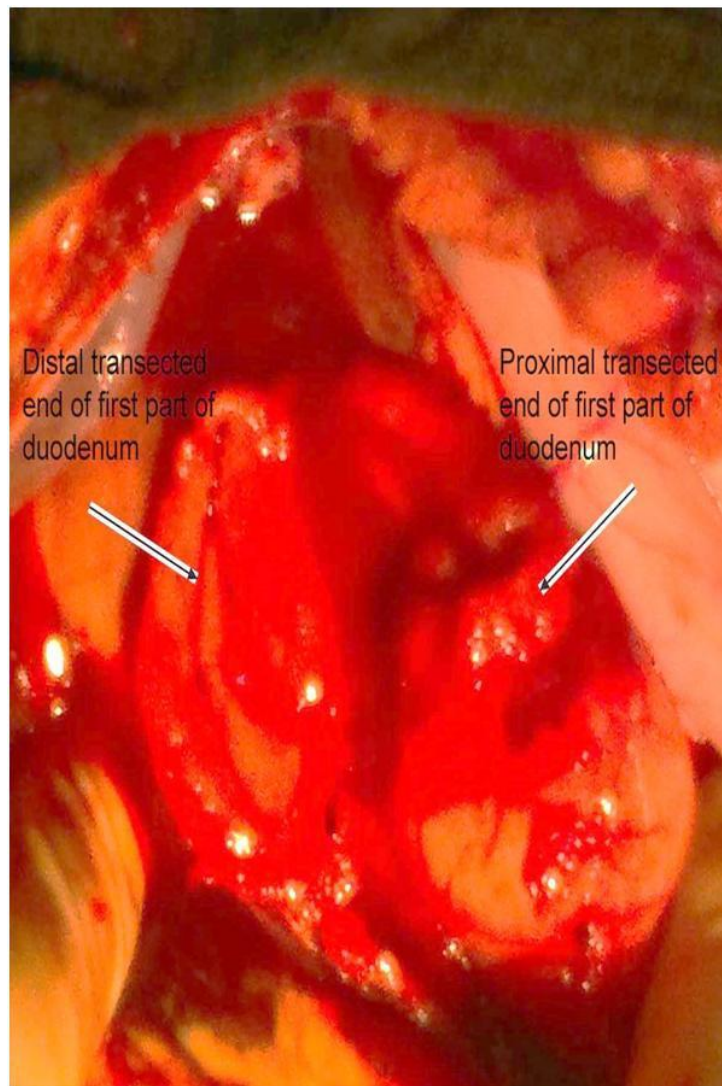
outcome.

## MATERIAL AND METHODS

In this study, which began from February 2011 till date, we encountered two duodenal injuries. In the first patient with carcinoid ileum having single hepatic metastasis in the left lobe of liver, there were dense intraoperative adhesions of first part of duodenum with ileum. During adhesiolysis, there was about 3 cm tear in the posterior wall of first and second part of duodenum. This tear was recognised and repaired intraoperatively using polyglactin 910 3-0 suture in two layers.

A young female was presented with eight hours prior history of blunt abdominal trauma. The abdominal paracentesis revealed haemoperitoneum. We immediately shifted the patient to operation theatre for urgent laparotomy. On laparotomy, there was laceration of superior mesenteric artery, right lateral retroperitoneal haematoma, complete circumferential transection at first

\*Corresponding author. E-mail: [khan\\_sachin12@gmail.com](mailto:khan_sachin12@gmail.com)



**Figure 1.** Proximal and distal transected ends of first part of duodenum.

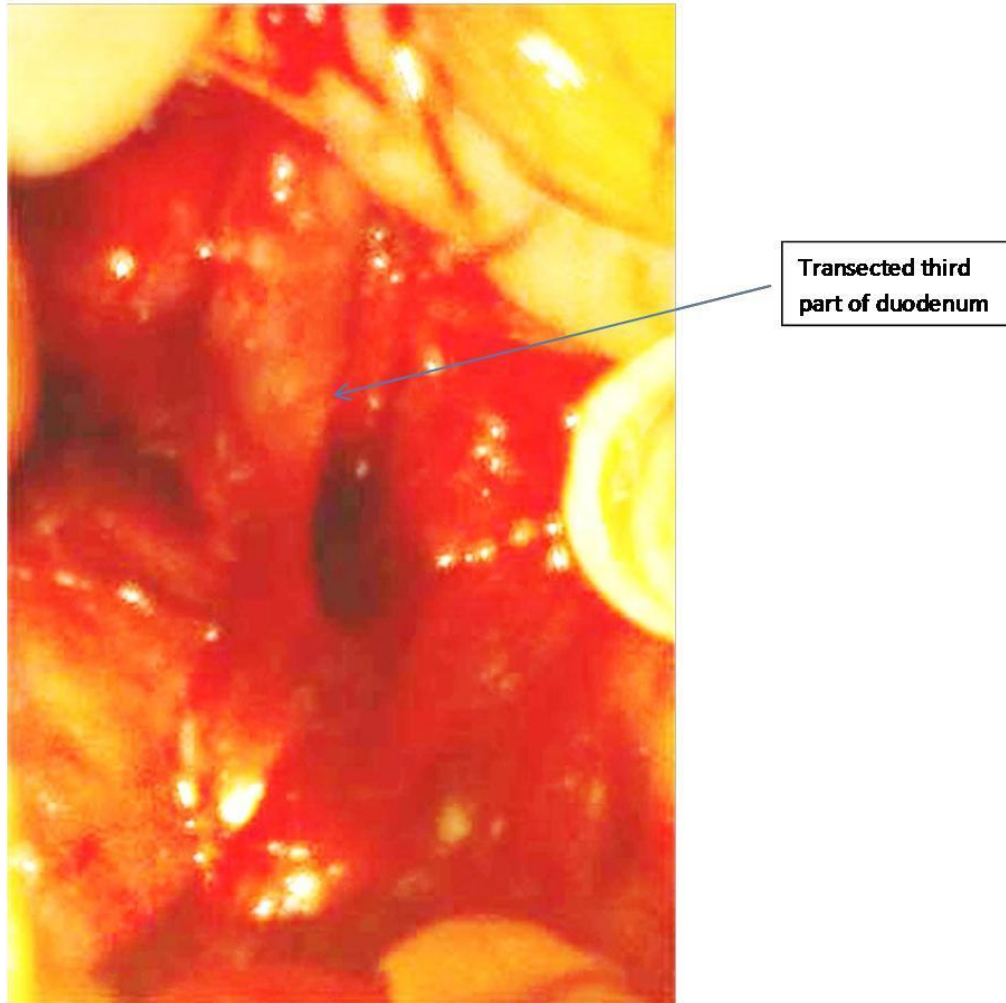
and third part of duodenum as shown in Figure 1. Distal transected stump of third part of duodenum was devitalized as shown in Figure 2.

Laceration in superior mesenteric artery as shown in Figure 3 was primarily repaired using polypropylene 5-0 suture. Duodenum was kocherized. Common bile duct, pancreas and second part of duodenum were found to be intact. Devitalized distal transected stump of third part of duodenum was closed. Loop of jejunum 15 cm distal to duodenojejunal junction was brought to be anastomosed to proximal transected third part of duodenum. We made a gastrostomy about an inch proximal to complete transection at first part of duodenum and passed a 16 Fr Foley catheter through gastrostomy across into first, second, third part of duodenum and then into jejunum. Duodenoduodenal anastomosis at first part and duodenojejunal anastomosis at third part was performed

over this stenting catheter with interrupted extramucosal sutures using polyglactin 910 3-0. Feeding jejunostomy was also performed.

## RESULTS

Our first patient had a normal postoperative outcome with no postoperative complication whatsoever. In another patient with double duodenal transection having superior mesenteric artery laceration, there was bile leak on first postoperative day from pericatheter site of stenting catheter. We removed 3 ml saline from balloon of this stenting catheter and bile leak stopped thereafter. Patient had a normal postoperative course. Stenting gastroduodenojejunal catheter was removed on 14th postoperative day and feeding jejunostomy was removed on 21st postoperative day.



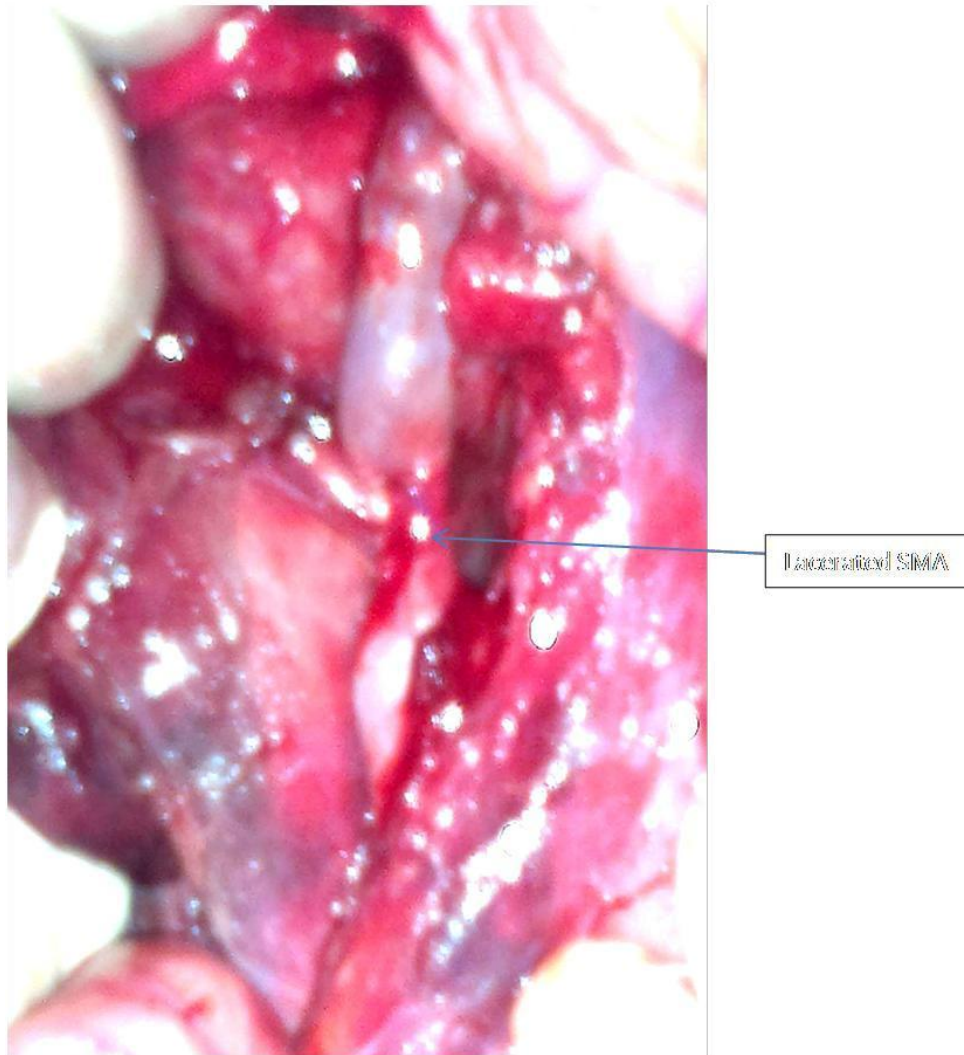**Figure 2.** Transected end of third part of duodenum.

## DISCUSSION

Zelic et al. (2010) used standard surgical techniques (median laparotomy, primary anastomosis, nasojejunal three-luminal tube for feeding and gastric decompression). They performed primary anastomosis of both transections with interrupted sutures in two layers. We did not use nasojejunal three-luminal tube. Rather we used Ryle tube, stenting gastrroduodenojejunal catheter and feeding jejunostomy. This stenting gastrroduodenojejunal catheter technique has not been practically reported in literature so far. Tip of this catheter is kept in proximal jejunum. This catheter serves two purposes – first to perform gastric, duodenal and jejunal decompression and second in event of anastomosis disruption, this catheter helps to localise and repair sites of anastomosis.

Reischl (2001) reported a case of an isolated complete duodenal avulsion distal to the pylorus after blunt abdominal trauma in a 78-year-old patient. He opined

that a duodenal injury in the case of blunt abdominal trauma is rare and amongst injuries to hollow organs is of no great importance. In isolated cases of duodenal injuries, it is normally the second or third section that is affected, both of which are fairly rigidly anchored to the retroperitoneum. If the first section is injured this is normally accompanied by considerable injury to the liver or head of the pancreas. Duodenal injuries are most feared injuries. Associated injuries can be diagnosed preoperatively by imaging if patient is haemodynamically stable. Imaging modalities were not used in any of our cases under study preoperatively. Computerised Tomogram (CT) scan is a good investigative modality but CT scan was not performed in any of our cases under study. This was as a result of the fact that the patient presented to us was either with haemoperitoneum and had to be urgently taken up for laparotomy, or injuries were diagnosed on table and were repaired intraoperatively. Since injuries were recognized and repaired intraoperatively, no other imaging was performed



**Figure 3.** Lacerated superior mesenteric artery.

performed in our cases under study. CT scan is a good investigative modality in elective cases or if patient's haemodynamic condition permits for these investigations. Duodenal injuries in both first and third part of duodenum was encountered, with significant right retroperitoneal haematoma. The study's technique of management, not yet reported in practical practice, has been associated with a successful outcome with no postoperative complications encountered.

Osuka et al. (2007) reported that blunt duodenal injury in children is uncommon and diagnosis is often delayed because of its retroperitoneal location. Both diagnosis and treatment are difficult. They reported the case of a 2-year-old boy whose trauma injury was not reported for 5 days. His vital signs were stable, but he was vomiting bile-stained fluid and his stools were white. The third portion of the duodenum was completely disrupted, and was repaired by pyloric exclusion with duodenal and bile

duct drainage. The child recovered uneventfully. Injuries in our patients under study were recognized and repaired early, with a successful outcome. Since the duodenal injuries were not associated with injury to common bile duct or second part of duodenum, pyloric exclusion or common bile duct drainage was not performed. The study's stenting gastroduodenojejunal catheter acted as a stenting as well a drainage catheter during postoperative period. However, it was assumed that the pyloric exclusion is no doubt an option, but maintaining normal bowel continuity if feasible, should be a preferable option in all cases. Moreover, third part of duodenum with loop of jejunum was anastomosed because distal transected end of third part of duodenum was devitalized.

This distal transected third part of duodenum been viable, we would have preferred duodenal anastomosis of third part over stenting 16Fr catheter, rather than duodenojejunal anastomosis been performed in our

study's patient.

McWhirter (2011) presented a case of delayed presentation of a traumatic duodenal rupture in a 15-year-old boy, presented 12 h after falling six feet and sustaining blunt trauma to his anterior abdominal wall. He underwent laparotomy and successful repair of the rupture and made an uneventful recovery and was discharged nine days later. McWhirter (2011) opined that duodenal rupture is a rare but serious complication of blunt abdominal trauma. Diagnosis is difficult but missed diagnosis and delayed presentation is associated with high morbidity and mortality. A high index for suspicion must be kept when dealing with blunt abdominal trauma to avoid being mistaken for duodenal injuries. It was considered that early diagnosis and corrective treatment of these rare injuries are associated with a successful outcome. Our study is of the opinion that primary repair of duodenal injuries in cases being presented early or recognized intraoperatively gives a good and successful outcome for patients.

Bittner and Roscher (1990) reported that though ruptures of the spleen and liver are comparatively frequent, traumas to the pancreas, stomach and duodenum belong to the rarities. Starting from 1982 to 1988, out of 218 surgically treated patients with a blunt abdominal trauma, they found only 1 duodenal rupture, 1 rupture of the stomach and 5 injuries to the pancreas. Whereas treatment of a gastric rupture is not a problem, treatment of a duodenal rupture depends on the type of rupture. Moreover, mortality is high ranging between 10 and 20%. Further, they opined that therapy depends on the degree of seriousness and has to be limited to a drainage operation in the individual case. This study is probably the first article showing rare management of rare duodenal injuries. Duodenal injuries are rare and double duodenal transections are rarest and only one case of double duodenal transection has been reported in world literature. Double duodenal transection with superior mesenteric artery laceration, as shown in one of our cases in this study, is yet to be reported in world

literature. Again we recommend early recognition and repair of duodenal injuries, coupled with this study's technique of primary anastomosis over stenting catheter especially in complete transections, which are rarest to encounter. This is a novel technique which is yet to be reported in world literature. However, this study is of the opinion that treatment has to be tailored as per patient. Primary anastomosis, if feasible should always be preferred over a stenting double lumen catheter, which serves dual purpose of stenting and drainage.

## REFERENCES

- Bittner R, Roscher R (1990). Stomach, duodenal and pancreatic injuries: diagnosis, surgical procedure. *Langenbecks Arch Chir Suppl II Verh Dtsch Ges Chir.* 1990; 617-623.
- McWhirter D (2011). Duodenal rupture following trauma in a child. *Scott Med. J.* 2011 May; 56(2): 120.
- Osuka A, Idoguchi K, Muguruma T (2007). Duodenal disruption diagnosed 5 days after blunt trauma in a 2-year-old child: report of a case. *Surg Today.* 2007; 37(11): 984-988. Epub 2007 Oct 25.
- Reischl M (2001). Isolated complete duodenal avulsion at the pylorus after blunt abdominal trauma. *Chirurg.* 2001 May; 72(5): 603-605.
- Zelić M, Kunisek L, Petrosić N, Mendrila D, Depolo A, Uravić M (2010). Double transection of complete duodenal circumference after blunt abdominal trauma without other intra-abdominal injuries. *Wien Klin Wochenschr.* 2010 Jan; 122(1-2): 54-56.