

Full Length Research Paper

# Histological and toxicological effect of wine from cashew fruits compared with imported red wine

S. Awe<sup>1\*</sup> and E. Tunde Olayinka<sup>2</sup>

<sup>1</sup>Department of Biological Sciences, Ajayi Crowther University, P. M. B. 1066, Oyo, Oyo State. Nigeria.

<sup>2</sup>Department of Chemical Sciences, Ajayi Crowther University, Oyo, Nigeria.

Accepted 09 July, 2014

*Saccharomyces cerevisiae* SIL 59703 was used to ferment cashew apple juice supplemented with 30% Sucrose in the laboratory incubated at room temperature ( $28 \pm 2^\circ\text{C}$ ) for six days (aerobic) and six weeks (anaerobic) for wine production. Toxicological effect of the wine produced was based on histology and enzyme activities of rats' liver. Forty-two rats were divided into three groups: group I (negative control) received no wine, group II subdivided into three sub groups A, B and C received 6.25 ml/kg body weight of 5, 7.5 and 10% alcohol content of the Red wine (positive control) respectively, while, group III also subdivided into three sub groups A, B and C received 6.25 ml/kg body weight of 5, 7.5 and 10% alcohol content of the cashew wine, respectively for eighteen days. Histological studies of the rat liver fed with both the red wine and cashew wine revealed marked alteration in cellular structure at 7.5 and 10% alcohol content which was not noticeable in the negative group. Enzyme activities indicated that both red wine and cashew wine at 7.5 and 10% alcohol content induced marked liver failure characterized by a significant increase ( $p < 0.05$ ) in serum aspartate ransaminase (AST), alanine transaminase (ALT), Lactate dehydrogenase (LDH) and Gamma glutamyl transpeptidase (GGT) activities. In conclusion, 5% alcohol content of the cashew wine showed no apparent disruptions of the normal liver structure by histological and enzyme activities assessment.

**Key words:** Enzyme activities, fermentation, histology, serum, wine.

## INTRODUCTION

Wine is an alcoholic beverage produced by normal alcoholic fermentation of the juice of ripe grapes by the natural yeasts found on the skin of the fruit or by using selected yeast such as *Saccharomyces cerevisiae* (Okafor, 1978). Other fruits such as apples, berries, blackcurrants, orange, water melon are sometimes also fermented for wine production (Berry, 2000). France, Italy and Germany produced over half the total world output of wine, although other countries in parts of the world are also involved in wine production (Lau and Jaworski, 2003).

Slinkard (2007) suggests that red wine protects against heart attack by interfering with production of a body chemical: endothelin-1 (ET-1) which clogs up arteries. However, the benefits are available only when wine is taken in moderate intake as over consumption of alcohol

including wine can cause some diseases such as cirrhosis of the liver and alcoholism (Jordan, 2002).

Cashew (*Anacardium occidentale* L.) is one of the important nut crops, ranking third in the international trade. Cashew apple is not a true fruit but a swollen peduncle to which the cashew nut is attached. It is a soft but fibrous juicy fruit. It possesses exotic flavor characteristics. Based on external color of the fruit, cashew apple can be broadly classified into red and yellow varieties.

Nigeria is blessed with a vast array of seasonal fruits, which are rich in sugars. The fruits are produced yearly in quintiles that are in excess of their consumption. Large quantities of those fruits are disposed off yearly due to non-availability of or poor storage facilities. These results in loss of the vital nutrients such as vitamins that are associated with it and potential revenue sources. If the fruits are put to other use such as wine production, the nutrients that are so lost can be harnessed and made available all year round. This study is aimed at assessing

\*Corresponding author. E-mail: [asflor5@yahoo.com](mailto:asflor5@yahoo.com).

the histological and toxicological effect of wine from cashew fruits compared with imported red wine.

## MATERIALS AND METHODS

### Fermenting organism

Pure culture of *S. cerevisiae* SIL 59703 was purchased locally and used to ferment the must.

### Preparation of cashew wine

Ripe, fresh and healthy cashew apple was weighted (9.8kg), surface sterilized with sodium metabisulphate solution to remove microbial contaminants. The apple was then chopped to bits, crushed with sterilized blender to produce 16 L of juice. The juice was then diluted to 24 L with warm water (45°C) to give the 'must' needed for wine production. Standardized campden tablet, 30% sucrose and yeast nutrient were added and allowed to stay for 24 h after which yeast was added (Berry, 2000).

### Aerobic fermentation

Standardized amount of yeast was added to 24 L of must in a fermenting jar by sprinkling it over the surface of the juice. The inoculated must was covered with muslin cloth and incubated at room temperature (28 ± 2°C). The fermenting must was aerated daily by stirring twice to encourage yeast multiplication (Berry, 2000). Aerobic fermentation was terminated after 6 days and the must was sieved to remove the shaft and debris of the crushed fruits.

### Anaerobic fermentation

The filtrate obtained after sieving the must was transferred into anaerobic fermentation jar and incubated at room temperature. An air trap was fixed to the fermenting jar. Campden tablet was added to the filtrate to supply sulfur dioxide gas. Fermentation was terminated after six weeks. The wine was then stored to allow the yeast to flocculate. The resulting wine was racked monthly for three months to clear the wine and then aged. After aging for 6 months, the wine was filtered using pressurized filtering kit, decanted into sterile bottles and corked.

### Experimental procedure

Animals weighing an average of 160g were bred and housed in the Animal House of the Department of Chemical science, Ajayi Crowther University, Oyo, Nigeria. They were kept in wire meshed cages and fed with commercial rat chow (Bendel feeds Nigeria ltd) and supply water ad libitum. Forty-two (42) albino rats (wistar strain) were divided into three groups:

**Group I** consist of only 6 rats served as the negative control to which only distilled water (no wine) was administered orally.

**Group II** consist of 18 rats divided into 3 subgroups A, B, C received 6.25 ml/kg body weight of 5, 7.5 and 10% alcohol content of the Red wine (positive control) respectively.

**Group III** consist of 18 rats divided into 3 sub groups A, B, C received 6.25 ml/kg body weight of 5, 7.5 and 10% alcohol content of the cashew wine respectively for eighteen days. After 18 days, the rats were sacrificed approximately 24 h after the last treatment.

### Collection of blood samples for serum preparation

The rats were sacrificed by cervical dislocation. Blood samples were collected via ocular punctures into plain bottles. Serum was prepared by aspiration of the clear yellowish liquid after clotting and centrifuged for 10 min at 3000 x g in an MSC (Essex, UK) bench centrifuge. Estimation of enzyme activities was done by using clear supernatant. The liver was immediately removed, blotted and fixed into 10% formaldehyde solution.

### Histological procedure

The method of Baker and Silverton (1972) was employed for the histology of the liver. The liver was section transversely in its biggest diameter with a steel blade and fixed in 10% formaldehyde solution for 24 h. After fixation, the liver section were dehydrated, cleared, infiltrated, embedded, sectioned and stained, using haematoxylin. After which the mounting was done using Canada balsam as the mountant after which the slides were examined using Leitz microscope and their photomicrographs taken and examined.

### Determination of serum aspartate ransaminase (AST) and alanine transaminase (ALT) activities

Serum AST and ALT activities were determined using Randox diagnostic kits. Determination of AST and ALT activities were based on the principle described by Reltman and Frankel (1957).

### Determination of serum lactate dehydrogenase (LDH) activities

Serum LDH activities were determined using Randox diagnostic kits following the principle described by Wroblewski and Ladue (1955).

### Determination of serum (gamma glutamyl transpeptidase) GGT activities

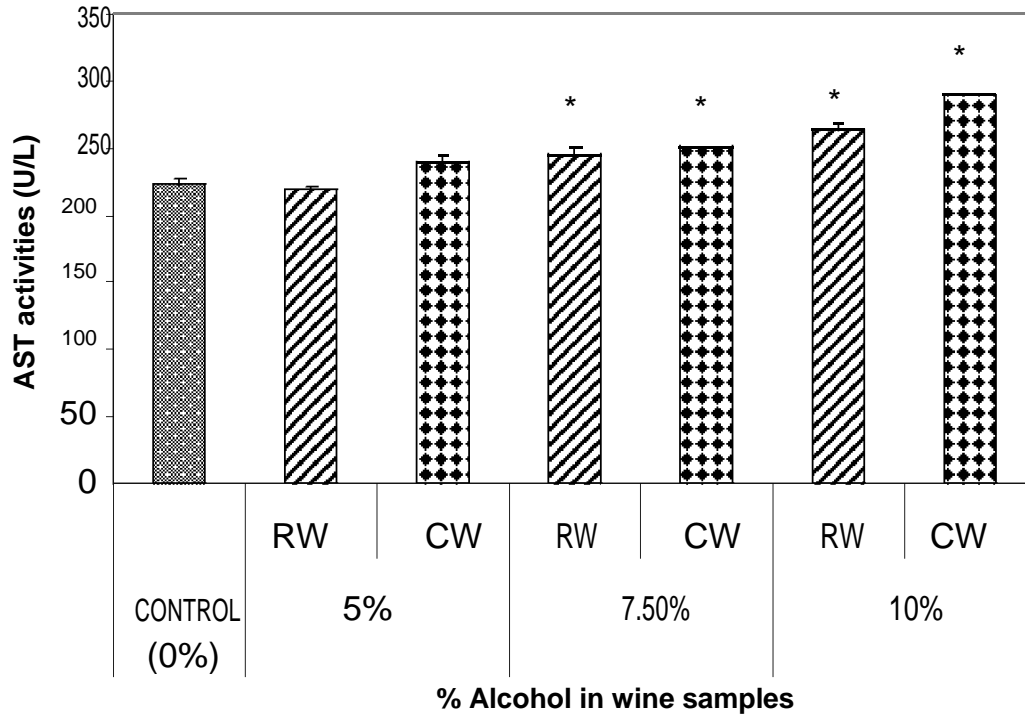
Serum GGT activities were determined using Randox diagnostic kits following the principle described by Szasz (1969).

### Statistical analysis

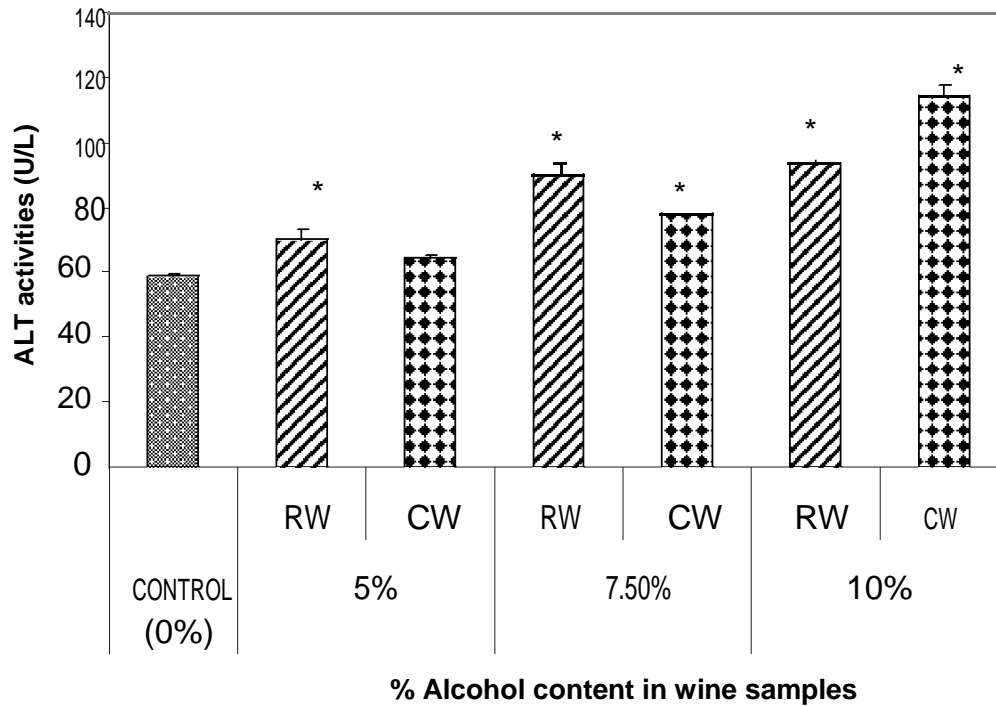
The data were analyzed using one way ANOVA followed by Duncan multivariable post-hoc test for comparison between control and treated rats in all groups. P values less than 0.05 were considered statistically significant.

## RESULTS

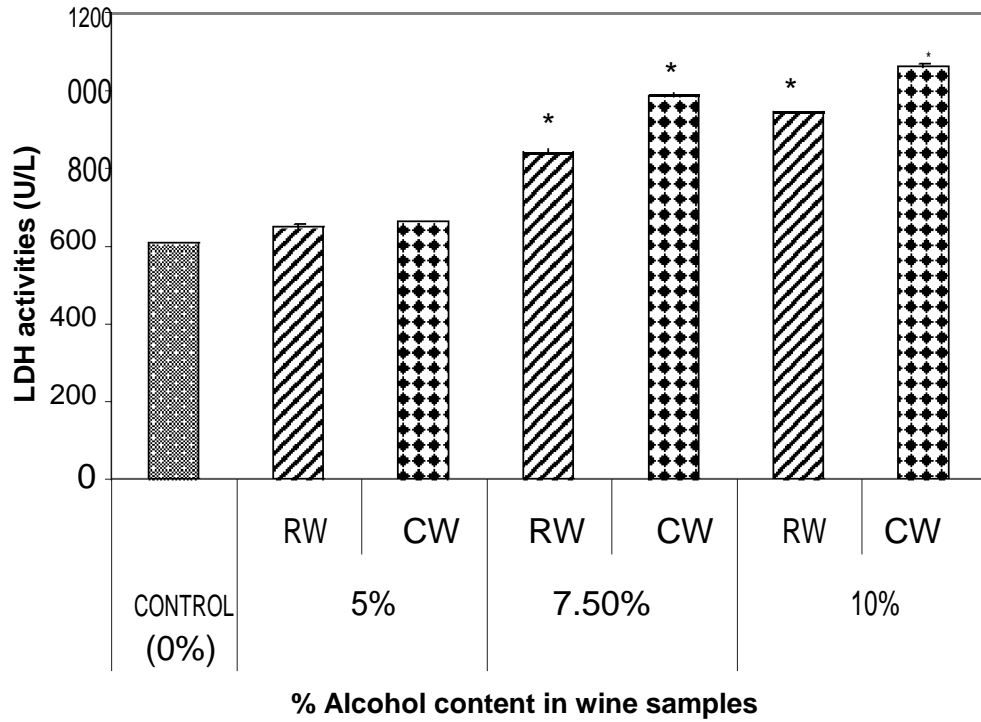
Figure 1 showed the effect of different wines of varying alcoholic contents on serum AST activities, while the effect of different wines of varying alcoholic contents on serum ALT activities was presented in Figure 2. Figures 3 and 4 showed the effect of different wines of varying alcoholic contents on serum LDH activities and GGT activities, respectively. All the results showed that there were a significant increased (p < 0.05) in the level of all the four enzymes activities in those rats treated with wines of 7.5 and 10% alcoholic content when compared with the control. However, at 5% alcoholic content the



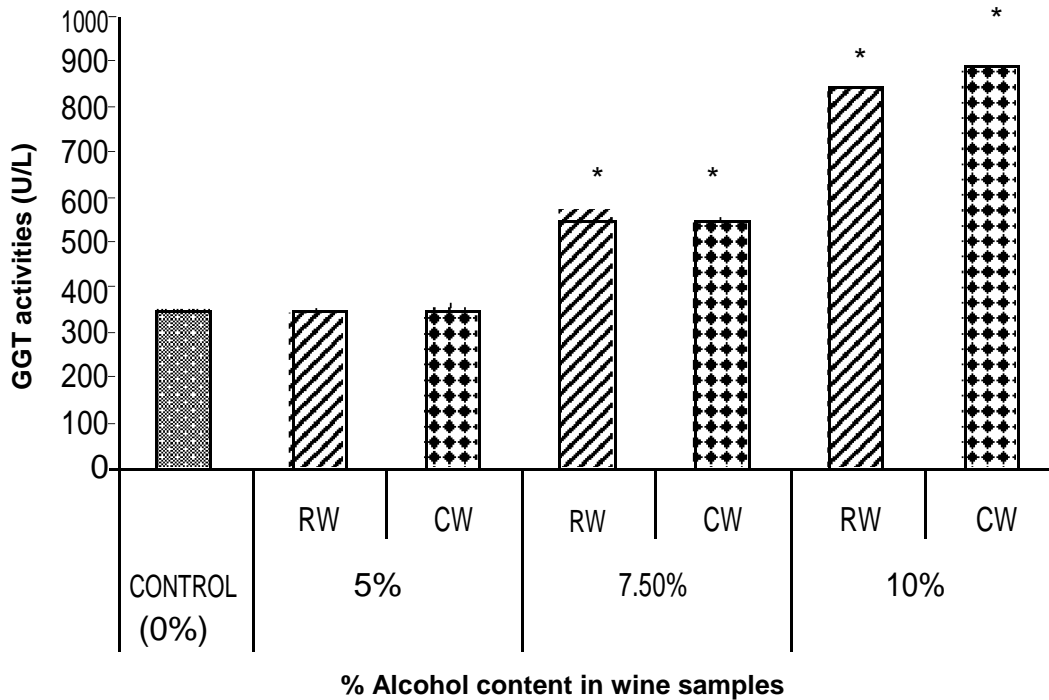
**Figure 1.** Effect of different wines of varying alcoholic contents on serum AST activities. Key: RW = Red Wine; CW = Cashew Wine. The values are the Means  $\pm$  SD (range) for six rats in each group. \* Significantly different from the control,  $p < 0.05$  (Duncan's multiple comparison test).



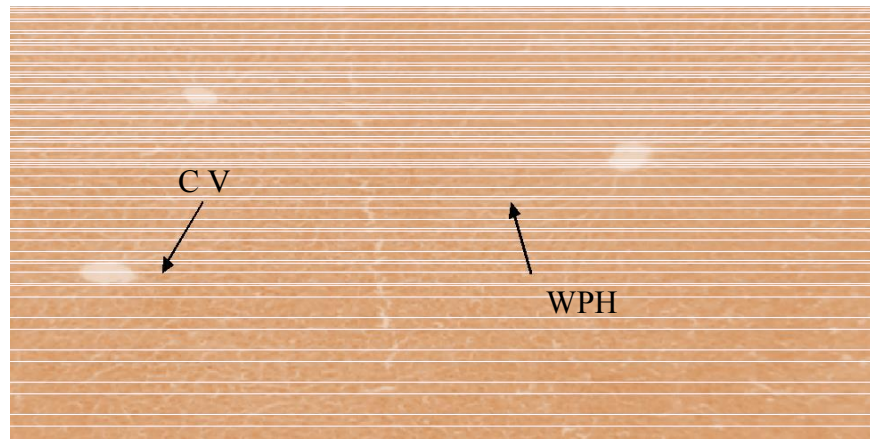
**Figure 2.** Effect of different wines of varying alcoholic contents on serum ALT activities. Key: RW = Red Wine; CW = Cashew Wine. The values are the Means  $\pm$  SD (range) for six rats in each group. \* Significantly different from the control,  $p < 0.05$  (Duncan's multiple comparison test).



**Figure 3.** Effect of different wines of varying alcoholic contents on serum LDH activities. Key: RW = Red Wine; CW = Cashew Wine. The values are the Means  $\pm$  SD (range) for six rats in each group. \* Significantly different from the control,  $p < 0.05$  (Duncan's multiple comparison test).



**Figure 4.** Effect of Different wines of varying alcoholic contents on serum GGT activities. Key: RW = Red Wine; CW = Cashew Wine. The values are the Means  $\pm$  SD (range) for six rats in each group. \* Significantly different from the control,  $p < 0.05$  (Duncan's multiple comparison test).



**Plate 1.** Photomicrograph (X120) showing effect of administration of distilled water (CONTROL) on architecture of liver of rats. (XH stain). Key: CV- central vein, - WPH- well preserved hepatocytes.

wine show no significant effect on the enzymes activities when compared with the control.

Plate 1 showed the photomicrographs of the normal liver architecture (negative control), while Plates 2 and 3 showed the photomicrographs of the liver cell treated with red wine and cashew wine as positive control at different alcohol content levels. The liver histology was significantly affected by administration of the wine at 7.5 and 10% alcohol level as characterized by mild and severe hyperplasia of central vein, distorted hepatocytes and degenerated area of fatty acid, while at 5.0% the liver structure was well preserved.

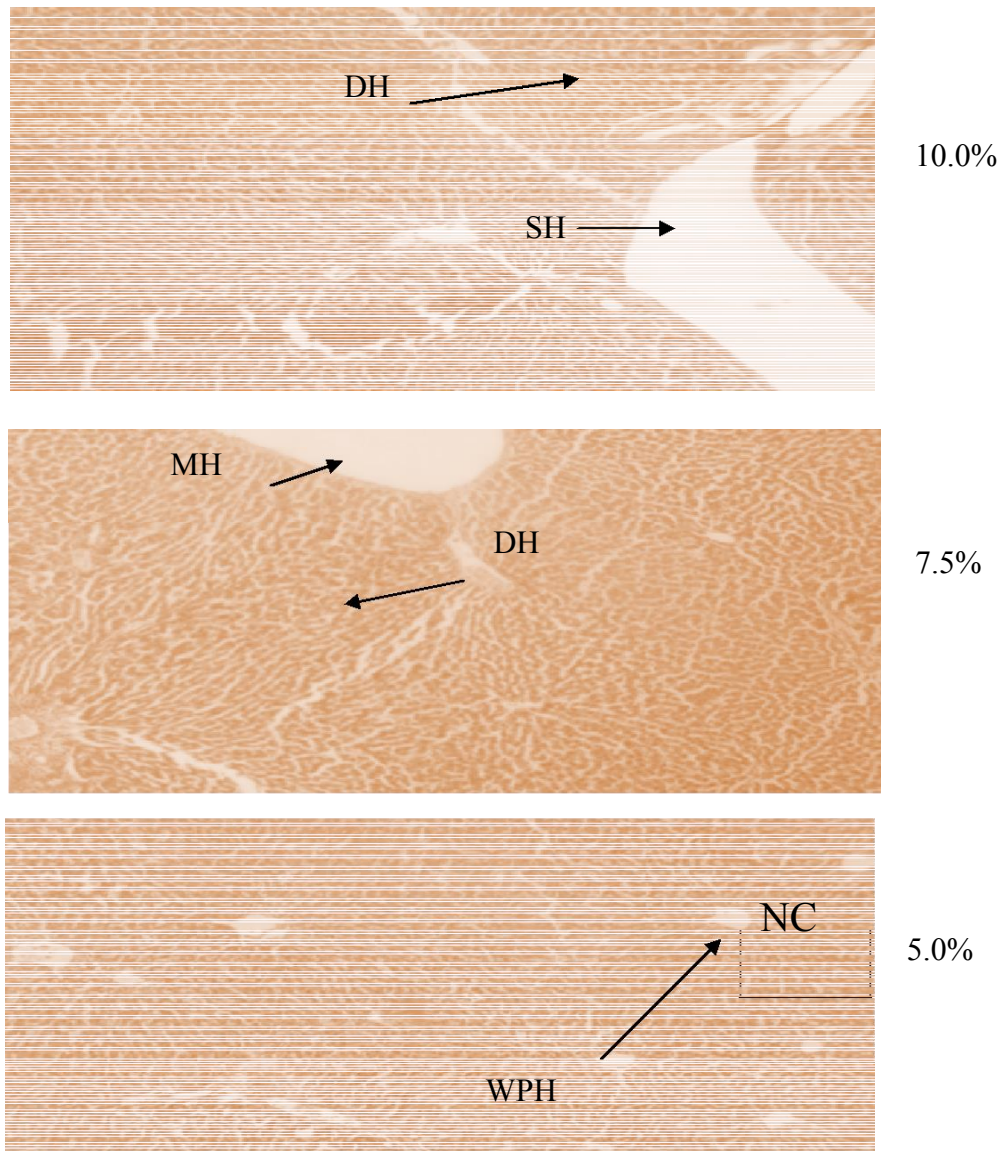
## DISCUSSION

Histopathological change in tissues is a late manifestation of a chemical, physical, mechanical or inflammatory assault on the tissue and usually complements enzyme studies. Administration of red wine and cashew wine at 5% alcohol content showed minimal effect on the liver histology (Plate 2 and 3). There were no apparent disruptions of the normal liver structure. However, administration at 7.5 and 10% alcohol content showed mild and severe hyperplasia. These suggest that administration of the wines at 7.5 and 10% alcohol contents could cause major histopathological changes. Jacquelyn and Maher (1997) reported that liver damage caused by alcohol and by-product of the metabolism such as acetaldehyde and highly reactive molecules such as free radicals. Similar effects were observed with the red wine and cashew wine produced that indicated that the wine comparable in terms of histopathological effects on the liver, hence the quality of the wines can be ascertained. The measurement of the various enzyme activities in the tissues and body fluids play a significant role in disease investigation, diagnosis and detection of tissue cellular damage (Akanji and Ngaha, 1989;

Malomo, 2000) . Tissues enzyme assay revealed that damages even before structural damages are detected by conventional histological techniques (Akanji, 1986). The marker enzymes assayed are specifically located in some cell; however, they can leak into the serum or other parts as a result of injury to the cell where they are located (Ngaha, 1982; Adesokan and Akanji, 2003; Jensen and Freese, 2009).

Low levels of AST is normally found in the blood, however, when the liver or heart is damaged additional AST is released into the bloodstream. It rises within 6 to 10 h and remains high for 4 days. ALT is produced within the cells of the liver and is the most sensitive marker for liver cell damage (Tietz, 1991; Jensen and Freese, 2009). Any form of hepatic cell damage can result in an elevation in the ALT; as the cells are damaged, the ALT leaks into the bloodstream leading to a rise in the serum levels. Therefore, the high AST and ALT levels in the serum of rats to which the wines (red wine and fruits wine produced) were administered are indications of leakage into the bloodstream due to liver damage (Sampson, 1980; Jacobs, 1996). AST and ALT are predominantly cytosolic enzymes but some are found in the mitochondria that are involved in transamination reactions in amino acid metabolism.

Adesokan and Akanji (2003) reported alterations in the concentration of these enzymes, following administration of drug and chemical agents, including alcohol. LDH is an enzyme found in the cells of many body tissues, including the heart and liver (Janis, 2006). Owing to its widespread distribution in the tissues, elevation of the total LDH in the serum is generally of little value in diagnosis. High values commonly occur after myocardial infarction, in megaloblastic anemia, progressive muscular dystrophies and in neoplastic diseases especially widely disseminated forms (Curtis and Roth, 1974; Ziegenhorn et al., 1978). Serum LDH is usually within the normal range in chronic renal disease associated with uremia, high



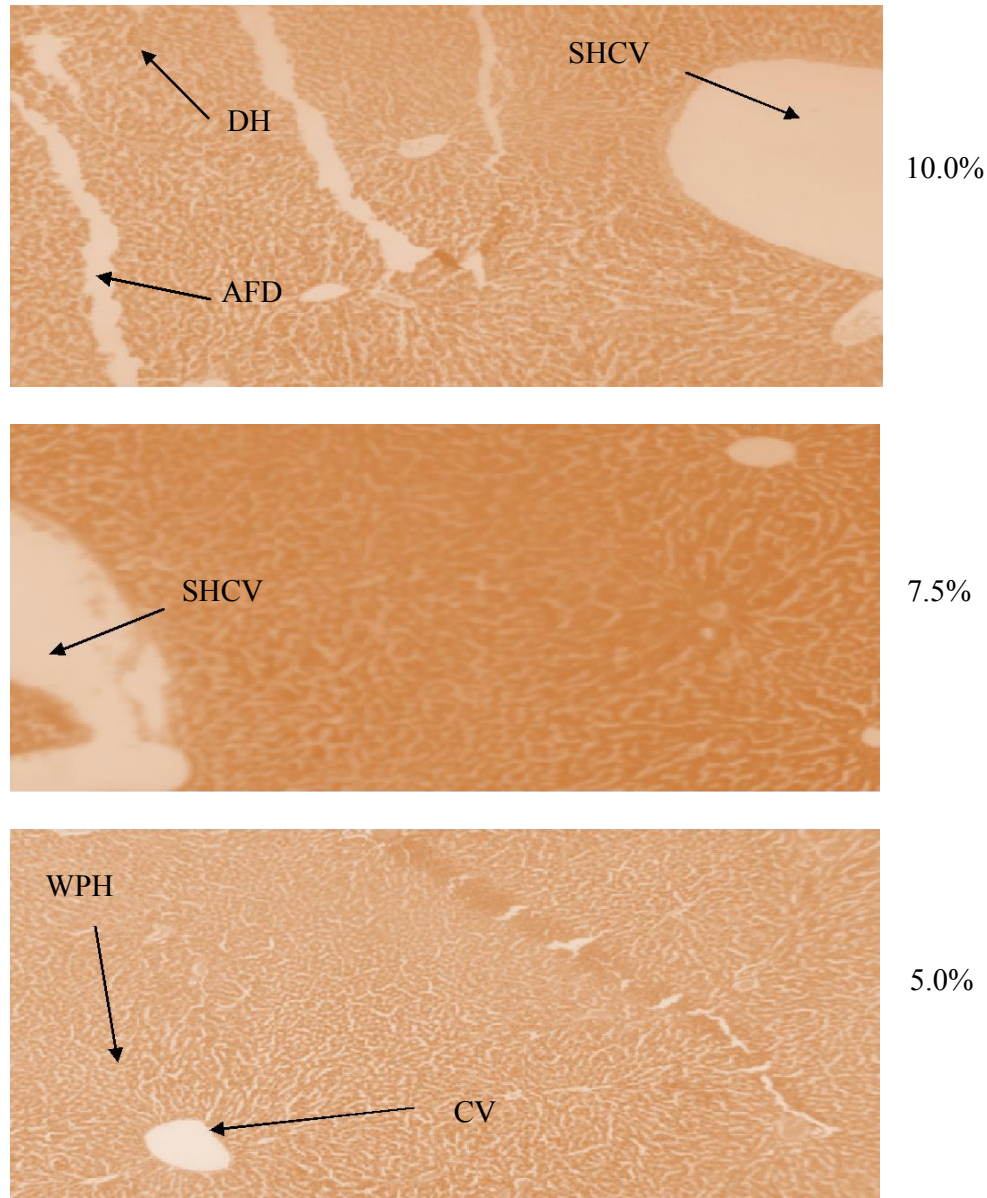
**Plate 2.** Photomicrograph (X120) showing effect of administration of red wine at different alcohol levels (5, 7.5 and 10%) on architecture of liver of rats. (XH stain), WPH- well preserved hepatocyte, SH-sever hyperplasia, MH-mild hyperplasia central vein, dh- distorted hepatocyte.

activities usually occur in infective hepatitis, mononucleosis and toxic jaundice in which hepatocellular damage occur.

The results of GGT activities in the rats serum showed that the activities were elevated in those that were administered 7.5 and 10 % wines, except those that were administered wine of 5% alcohol content. GGT is a membrane bound glycoprotein found in cells with a high secretion or absorption activity (e.g. liver, kidney, pancreas and intestine) produced by the bile ducts It is believed to be involved in the amino acids and peptides transportation into cells as well as glutathione metabolism. Jensen and Freese (2009) reported that certain GGT levels reflect rare forms of liver disease and

alcohol can cause increases in the GGT. The significant elevation of the enzyme activities by the wine in the serum needs further assessment through liver test functions. The result of the enzyme activities clearly demonstrated that the effect of the wines was dose dependent. Generally the wine consumption affected the liver structure or cells which confirmed by Akanji (1986) studies that tissue enzyme assay detect liver damage before structural damages are detected by conventional histological technique.

It is concluded that the toxicological effect exhibited by 5% alcohol content of the cashew wine with no apparent disruptions of the normal liver structure by histological and enzyme activities assessment.



**Plate 3.** Photomicrograph (X120) showing effect of administration of cashew wine at different alcohol levels (5, 7.5 and 10%) on architecture of liver of rats. (XH stain). WPH- Well preserved Hepatocyte, SHCV- severe hyperplasia central vein, MH-mild hyperplasia central vein, DH-distorted hepatocyte, AFD- area of fatty acid degeneration, CV- central vein.

## REFERENCES

- Adesokan AA, Akanji MA (2003). Effect of administration of aqueous extract of *Enantia chlorantha* on the activities of some enzymes in the small intestine of rats. *Nigeria J. Biochem. Mole. Biol.*, 18(2): 103-105.
- Akanji MA (1986). A Comparative Biochemical Study of Interaction of Some Trypanocides with Rat Tissue Cellular System Ph.D Thesis. University of Ife, Ile-Ife.
- Akanji MA, Ngaha EO (1989). Effect of repeated administration of beremil on urinary excretion with corresponding tissue pattern in rats. *Pharmacol. Toxication* 64: 272-275.
- Baker FJ, Silverton RE, Luckcock ED (1972). *Haematological Indices in: Introduction to Medical Laboratory Technology*. Fourth Ed. Butterworth and Co. Ltd., p. 558-562.
- Berry CJJ (2000). *First steps in wine making*. Published by GW Kent, Inc. 3667 Morgan Road, Ann Arbor MI 48108, p. 235.
- Curtis HC, Roth M (1971). *Clinical implication of lactate dehydrogenase, clinical biochemistry principles and methods vol 2 ch II*. Water deGruyter, Berlin, p. 614-617.
- Jacquelyn J, Maher MD (1997). *Exploring Alcohol's Effect on Liver Function*. *Alcohol Health Res. Word*, 21: 1.
- Janis OF (2006). *Gale Encyclopedia of Medicine*. Published by the Gale Groups. pp. 216-221.
- Jensen JE, Freese D (2009). *Liver Function Tests*. Colorado Center for Digestive disorders 205s. Suite A Longmont Co. 80501. Pp 151-163
- Jacobs MB (1996). *The Chemistry Analysis of food and food product*. 3<sup>rd</sup> Edition CBS publishers and Distributors, New Delhi India, p. 250.

- Jordan D (2002). An Offering of Wine, Doctoral Thesis, The department of Semitic Studies University of Sydney. ([http://ses.library.usyd.edu.au/bitstream/2123/482/1/at-NU2003\\_1211.15583702\\_whole.pdf](http://ses.library.usyd.edu.au/bitstream/2123/482/1/at-NU2003_1211.15583702_whole.pdf)).
- Lau CK, Jaworski JF (2003). Industrial Sustainability through Biotechnology ASM News, 69: 110-111.
- Malomo SO (2000). Toxicological implication of Ceftriaxome administration in rats. Nig. J. Biochem. Mol. Biol., 15(1): 33-35.
- Ngaha EO (1982). Further studies on the in vivo effect of Cephaloridine on the stability of rat kidney lysosomes. Biochem. Physical, 8: 1843-1847.
- Okafor N (1978). Industrial Microbiology. University of Ife Press Ltd., p. 413.
- Reltman S, Frankel S (1957). A colorimetric method for the determination of serum ALT and AST. Am. J. Clin. Pathol., 28: 56-63.
- Sampson EJ, Wheeler VS, Buntis CA, Mc Knenily SS, Fast DM, Daye DD (1980). An Inter-Laboratory Evaluation of the IFCC Method for Aspartate Aminotransferase with use of purified Enzyme Materials Clin. Chem., 26: 1156-1164.
- Slinkard Stacy (2007). Wine: Red for health – The Guardian (life), 12(14): 10-11.
- Szasz G (1969). Reaction rate method for gamma-glutamyl transaminase activities in serum. J. Clin. Chem., 22: 205-210.
- Tietz NW (1991). Fundamental of Clinical Chemistry. 3<sup>rd</sup> Edition. W.B. Sanders Co. Philadelphia, pp. 391-395.
- Ziegenhorn J, Brandhuber M, Bartl K (1978). Enzyme in health and Diseases. Soc. Clin. Enzymol. Karger, Basel, p. 131.