

Case Report

Surgical management of acquired anterior diaphragmatic hernia via laparoscopy

Abdullah Alwabari, Lalit Parida and Ahmed H. Al-Salem*

Division of Pediatric Surgery, Department of Surgery, King Fahad Specialist Hospital, Dammam, Saudi Arabia.

Accepted 25 November, 2023

Congenital diaphragmatic hernia is a relatively common condition with an incidence of about 1 in 2000 to 1 in 5000 live births. Most cases occur posterolaterally through the foramen of Bochdalek and usually present immediately after birth with respiratory distress. Congenital anterior diaphragmatic hernia (Morgagni's hernia) is rare, accounting for less than 5% of all types of congenital diaphragmatic hernias. Most of these cases are seen in older children and are usually asymptotically discovered incidentally or during investigations for some other unrelated condition. Iatrogenic anterior diaphragmatic hernia on the other hand is extremely rare. This report describes an iatrogenic anterior diaphragmatic hernia in a 6-month-old child following cardiac surgery that was repaired laparoscopically. The literature on the subject is also reviewed.

Key words: Anterior diaphragmatic hernia, Iatrogenic, laparoscopic repair.

INTRODUCTION

The majority of congenital diaphragmatic hernias occur through the foramen of Bochdalek (Cullen et al., 1985; Simson and Eckstein, 1985). Anterior diaphragmatic hernia (ADH) on the other hand is rare (Pokorney et al., 1984; Al-Salem, 2007; Zani and Cozzi, 2008). Most of the cases reported in the literature are congenital (Morgagni's hernia). Acquired anterior diaphragmatic hernias on the other hand are very rare and usually seen following blunt or penetrating trauma. Iatrogenic anterior diaphragmatic hernia is extremely rare and only three cases were reported in children (Bettolli et al., 2008; Dutta and Albanese, 2007). This report describes the fourth iatrogenic anterior diaphragmatic hernia in a child that was repaired laparoscopically.

CASE REPORT

A 6-month old male infant was referred to our hospital because of recurrent chest infections and failure to thrive. He was a product of full term normal vaginal delivery. His evaluation and investigations at that time revealed

obstructed infra-cardiac total anomalous pulmonary venous drainage and atrial septal defect which was repaired at 6 weeks of age. Subsequently, he had two episodes of pneumonia requiring hospitalization and intensive care. Physical examination revealed an emaciated infant with stable vital signs, median sternotomy scar, and scaphoid abdomen. Air entry was reduced bilaterally. Chest X-ray and barium enema demonstrated anterior diaphragmatic hernia with herniated transverse colon on both sides (Figures 1 and 2). His laboratory parameters were normal. He was planned for laparoscopic repair of the hernia. Laparoscopy was done using three ports (5 mm each). One just beneath the umbilicus for the camera and two in the upper abdomen, one on the left and one on the right along the midclavicular line. This revealed a 4x3 cm anterior and centrally located diaphragmatic defect with most of the transverse colon and part of left lobe of liver herniating through it (Figure 3). Part of the left lobe of the liver was herniating on the right side while the transverse colon was herniating on both sides. The herniating contents were reduced back into the abdomen. There were also omental adhesions in the retro-sternal space. The adhesions were released using a hook with cautery and the diaphragmatic defect was then closed with interrupted 2/0 Ethibond sutures (Figure 3). He required

*Corresponding author. E-mail: ahsalsalem@hotmail.com.

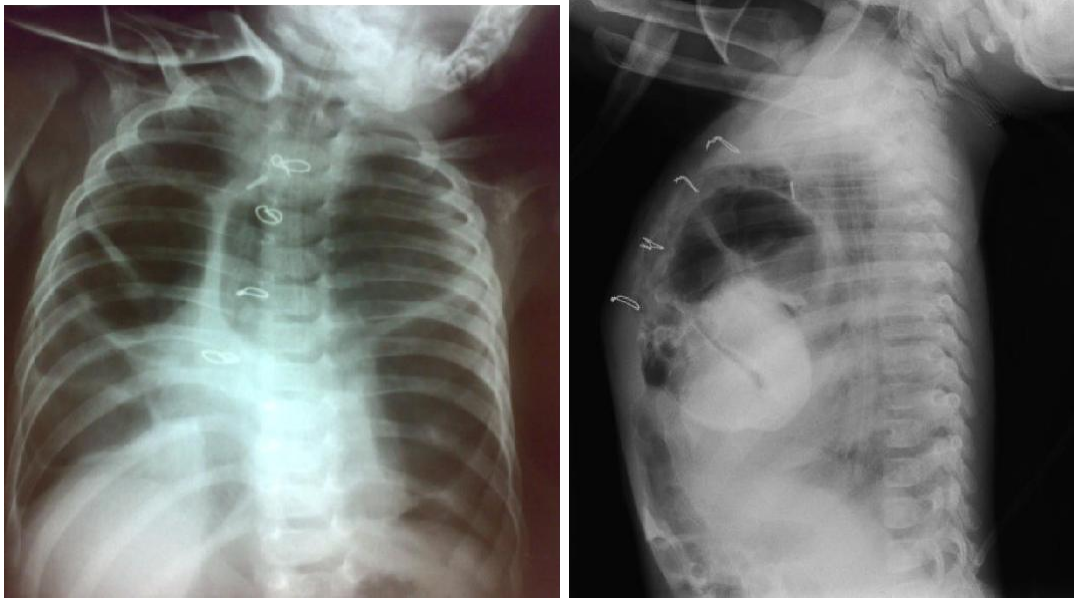


Figure 1. Antero-posterior and lateral chest x-ray showing anterior herniation of bowel loops into the chest. Note the wire from the previous cardiac surgery.

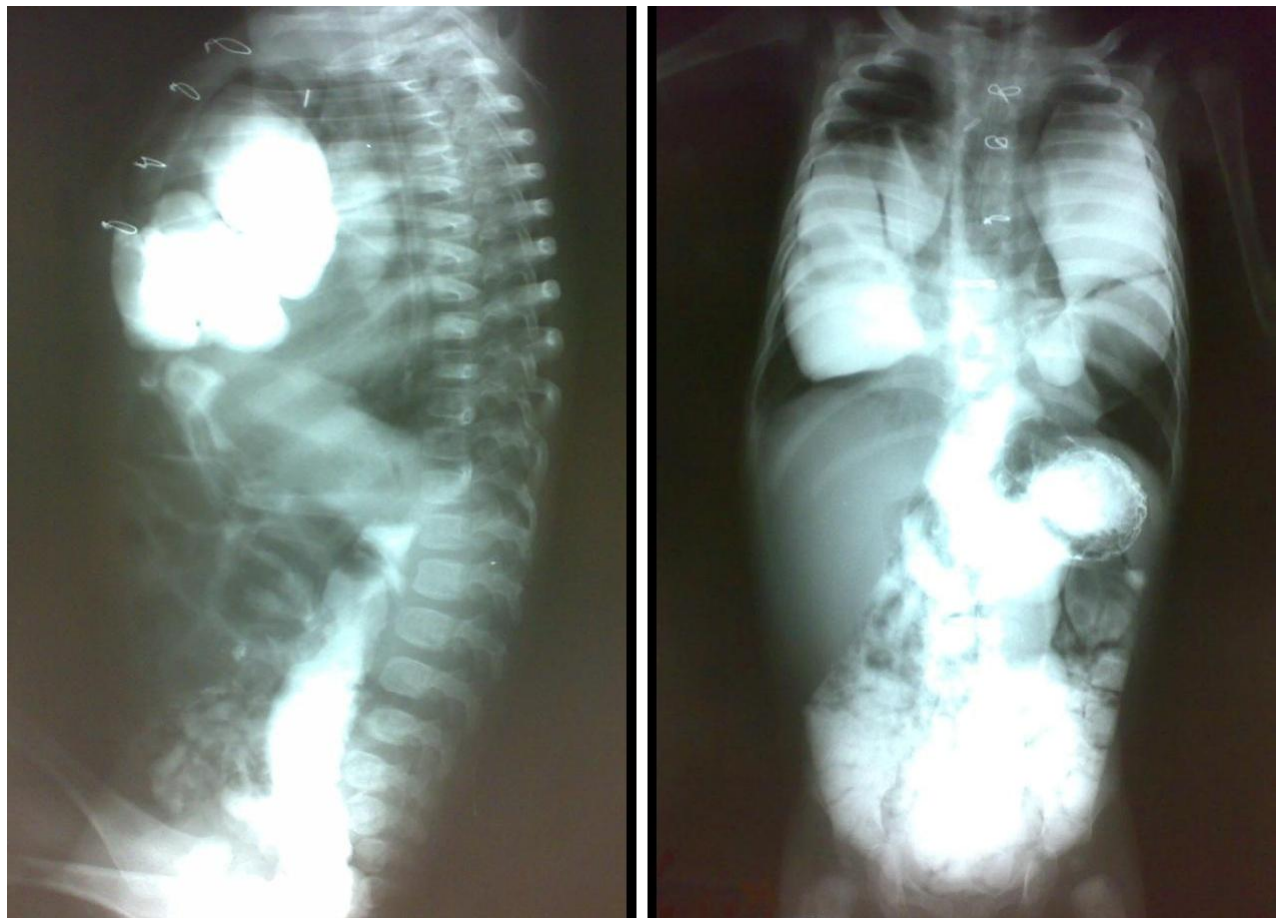


Figure 2. Upper contrast study showing anterior herniation of the colon into the chest. Note also the bilateral herniation of the colon into the chest.

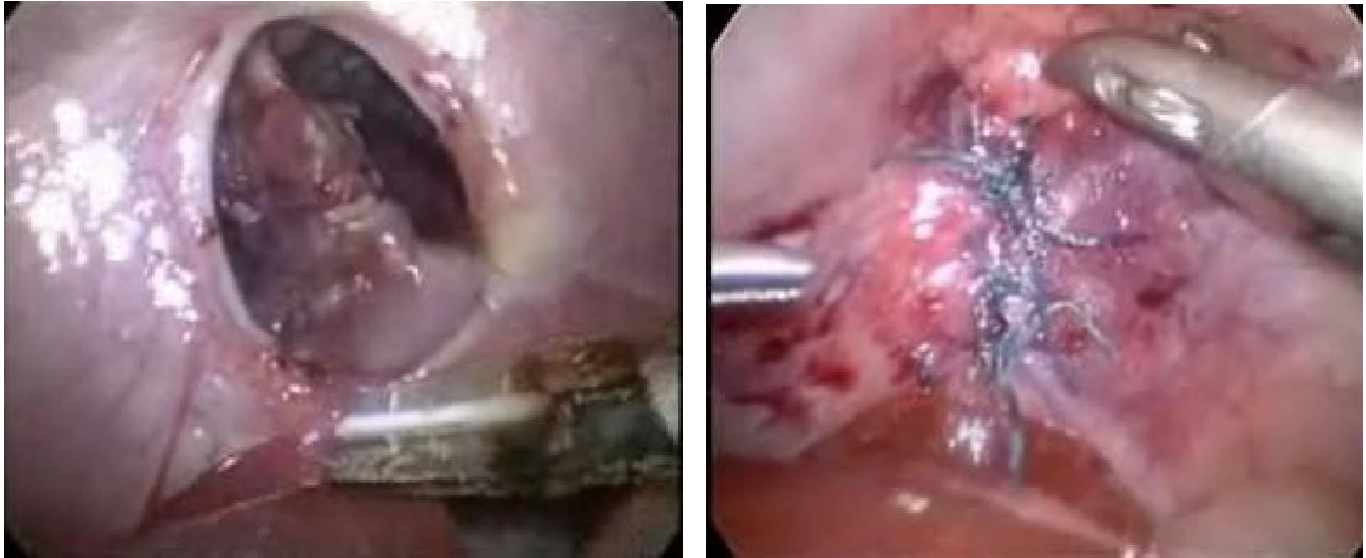


Figure 3. Intraoperative picture showing the centrally located anterior diaphragmatic hernia pre and post repair.

elective post-operative mechanical ventilation for 3 days and subsequently, extubated and discharged home in good general condition. He is now one year following surgery, well and gaining weight.

DISCUSSION

Herniation through the foramen of Morgagni (CMH) is rare. It makes up less than 5% of all types of congenital diaphragmatic hernias (Pokorney et al., 1984; Al-Salem, 2007; Berman et al., 1989; Vaos and Skondras, 2006). Acquired ADH on the other hand is rare and usually seen following penetrating or blunt trauma. Very rarely acquired ADH can be iatrogenic. There are only three cases of acquired ADH reported in the pediatric age group (Bettolli et al., 2008; Dutta and Albanese, 2007). All the three cases were seen following cardiac surgery. Bettoli et al. (2008) reported two children with asymptomatic, iatrogenic ADH that were diagnosed at 6 and 12 months of age, respectively. Both of them had undergone previous cardiac surgery requiring pericardial drainage. The ADH was seen on an incidental chest X-ray in one patient, and during a laparoscopic-assisted gastrostomy in the other. Dutta and Albanese (2007) reported seven patients (6 male, 1 female) with Morgagni's hernia, 6 of them had CHM while the other was thought to have an iatrogenic hernia following a sternotomy for heart surgery. Our patient had cardiac surgery with pericardial drainage and his hernia was symptomatic. He was admitted twice to the intensive care because of chest infection as well as failure to thrive. Iatrogenic ADH is anterior and central in position. This differentiates them from the congenital ADH which is usually to the side, more commonly on the right but can

be on the left or bilateral. We feel that the pericardial drains contribute to the development of this hernia. The opening created by the drain does not close on its own in some of these patients and the negative intrathoracic pressure contributes to bowel herniation into the chest which starts small and increases gradually. Adding to this, the effect of sternotomy weakens the central tendon of the diaphragm. Vrtik et al. (2006) reported two adult cases of poststernotomy mediastinitis and sternal wound reconstruction with a pedicled omental flap that were complicated by a large anterior diaphragmatic hernia containing the large bowel.

There is a general consensus that in symptomatic patients, CMH should be treated surgically. Opinions however differ as to the best surgical approach, whether trans-thoracic or trans-abdominal (Kilic et al., 2001; Al-Salem, 2007). Mert and Gunay (2006) used a transsternal approach to simultaneously repair Morgagni hernia in a patient with coexistent ventricular septal defect and Down syndrome). The recent advances in minimal invasive surgery has made laparoscopic repair of CMH safe and effective (Dutta and Albanese, 2007; Papia et al., 2004; Azzie et al., 2004; Lima et al., 2000; Georgacapulo et al., 1997). This can be accomplished either by direct closure of the defect using non-absorbable sutures like in our patient or more simply by using the technique of percutaneous placement of sutures (Azzie et al., 2004). Rarely, a prosthetic patch is required to close a large ADH laparoscopically (Dutta and Albanese, 2007). Laparoscopic repair of anterior diaphragmatic hernia is superior to the conventional open surgery and the benefits are reduced surgical trauma, shorter operative time, early commencement of full feeds, less post-operative analgesia, rapid and uneventful recovery, shorter hospital stay and better cosmetic

results (Alqahtani et al., 2011). Laparoscopic repair should be considered the procedure of choice for the treatment of anterior diaphragmatic hernia in infants and children.

Conclusion

In conclusion, iatrogenic anterior diaphragmatic hernia, although very rare, should be considered as a possible complication in children who had cardiac surgery. We feel laparoscopic repair is feasible and safe and should be considered the standard procedure for the treatment of iatrogenic anterior diaphragmatic hernia.

REFERENCES

- Alqahtani A, Al-Salem AH (2011). Laparoscopic-assisted Versus Open Repair of Morgagni Hernia in Infants and Children. *Surg. Laparosc. Endosc. Percutan. Tech.*, 21 (1): 46–49.
- Al-Salem AH (2007). Congenital hernia of Morgagni in infants and children. *J. Pediatr. Surg.*, 42:1539-1543.
- Azzie G, Maoate K, Beasley S, Retief W, Bensoussan A (2004). A simple technique of laparoscopic full-thickness anterior abdominal wall repair of retrosternal (Morgagni) hernia. *J. Pediatr. Surg.*, 39(2):249-250.
- Berman L, Stringer DA, Ein SH, Shandling B (1989): The late presenting pediatric Morgagni hernia: a benign condition. *J. Pediatr. Surg.* 24: 970-972.
- Bettolli M, Jackson CC, Sweeney B, Rubin S (2008). Iatrogenic anterior diaphragmatic hernia in childhood. *Eur. J. Pediatr. Surg.*, 18(4):275-276.
- Cullen ML, Klein MD, Philippart AI (1985): Congenital diaphragmatic hernia. *Surg. Clin. North Am.* 65: 1135-1138.
- Dutta S, Albanese CT (2007). Use of a prosthetic patch for laparoscopic repair of Morgagni diaphragmatic hernia in children. *J. Laparoendosc. Adv. Surg. Tech.*, 17(3):391-394.
- Georgacapulo P, Franchella A, Mandridi G, et al (1997). Morgagni-Larry hernia correction by Laparosc. *surg. Eur. J. Pediatr. Surg.*, 7: 241-242.
- Kilic D, Nadir A, doner E, et al (2001). Transthoracic approach in surgical management of Morgagni hernia. *Eur. J. Cardiothorac. Surg.*, 20: 1016-1019.
- Mario L, Marcello D, Michele L, Antonino M, Giovanni T, Remigio D (2000). Laparoscopic repair of Morgagni-Larry hernia in a child. *J. Pediatr. Surg.*, 35:1266-1268.
- Mert M, Gunay L (2006). Transsternal repair of Morgagni hernia in a patient with coexisting ventricular septal defect and Down syndrome. *Acta. Chir. Belg.*, 106:739-740.
- Papia G, Gerstle JT, Langer JC (2004). Laparoscopic repair of Morgagni Diaphragmatic hernia in children: Technical changes and results. *Pediatr. Endosurg. Innov. Tech.* 8:245-249.
- Pokorney WJ, McGill CW, Herberg FJ (1984): Morgagni hernia during infancy: presentation and associated anomalies. *J. Pediatr. Surg.*, 19: 394-397.
- Simson JNL, Eckstein HB (1985): Congenital diaphragmatic hernia: A 20 years experience. *Br. J. Surg.* 72: 733-736.
- Vaos G, Skondras C (2006). Colonic necrosis because of strangulated recurrent Morgagni's hernia in a child with Down's syndrome. *J. Pediatr. Surg.*, 41(3):589-591.
- Vrtik M, Cameron D, Edwards MG (2006). Sternotomy reconstruction with omentum followed by large diaphragmatic hernia. *Asian Cardiovasc. Thorac. Ann.*, 14:14-16.
- Zani A, Cozzi DA (2008). Giovanni Battista Morgagni and his contribution to pediatric surgery. *J. Pediatr. Surg.*, 43(4):729-733.