

Full Length Research Paper

Knotted multilength ureteral stent proximal to impacted mid-ureteric stone

Harfeil MN and Hasan RM

Urology department, King Abdulla Medical City, Mecca, Kingdom of Saudi Arabia.

Accepted 24 February, 2015

The use of ureteral stents has become one of the most common utilized tools in the era of endourology armamentarium. The indications for their placement have expanded significantly; however, their use is not free of complications and consequences. Stent knotting is uncommon complication when using multilength coiled stents; hereby we present a case of using ureteroscopy and Holmium laser to manage a knotted stent proximal to a mid-ureteric stone. After we reviewed literature, we found that knotting of multilength ureteral stents represents a rare complication that might be a significant challenge to the endourologists. Selection of the correct length of stent and assuring good position with x-ray guidance during insertion and removal might help to avoid this complication.

Key words: Ureter, knotted ureteral stent, stones, urological complications.

INTRODUCTION

Indwelling ureteral stents are essential in urology today, mainly in the management of upper urinary tract obstruction, urinary diversion, and postoperative drainage (Ahallal et al., 2010). Modern indwelling ureteral stents were first described by Zimskind *et al.* in 1967 (Zimskind PD et al., 1967). No ideal stent has been designed, and their use is not free of complications or consequences. A rare complication is knotting of an indwelling ureteral stent at its proximal coiled end, with only 14 cases previously reported in the literature (Picozzi et al., 2010).

Management of this complication in those studies varied with simple traction, three days of continuous staged traction, percutaneous removal, untying the knot by grasping the upper end of the stent using ureteroscopy, and untying the knot using amplatz super stiff guide wire. Open surgery has been reported in one case (Picozzi et al., 2010), and ureteroscopy with Holmium laser was also used in treating a case of a retained double J stent that coiled around itself, forming a knot in the proximal ureter (Richards et al., 2011).

In this report we present a case of knotted multilength ureteral stent proximal to impacted mid-ureteral stone, which was managed successfully using Holmium laser and ureteroscopy for stone manipulation and stent

extraction.

CASE REPORT

A 50-year-old male patient underwent right ureteral stent insertion for 1.5 cm mid-ureteric impacted stone. A 7 Fr multi-length stent was placed under fluoroscopic guidance. The patient's post-operative recovery was uneventful and he was discharged from hospital the same day after the surgical procedure. Three weeks later, the patient came to our Urology Department for removal of the ureteral stent and stone extraction. Slight difficulty while extracting the stent was noted by the operator, the distal tip of the stent was pulled out gently to the tip of the urethra, and trial of glide wire cannulation failed to pass through the stent, which was coiled directly proximal to the stone as evident by x-ray. [Figure 1]. The stent was fixed by a hemostat at the tip of urethra; retrograde uretrography showed smooth ureter distal to the stone and almost complete obstruction above it. Holmium laser was used to disintegrate the stone, through 8 Fr semirigid ureteroscopy, resulted in stent removal by constant traction under continuous fluoroscopic guidance. Examination of the extracted stent revealed a knot in its proximal J [Figure 2, 3]. An endoscopic evaluation was carried out to exclude any damage or bleeding from the ureter, and a Double Pig tail

*Corresponding author. E-mail: tekno_doc@yahoo.com

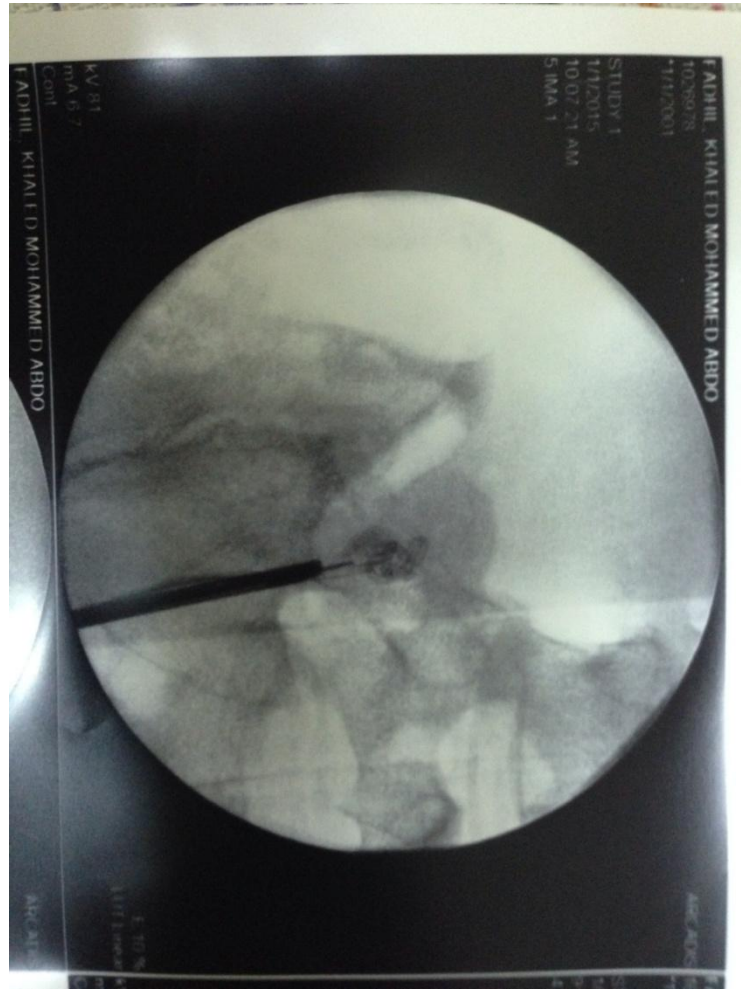


Figure 1.

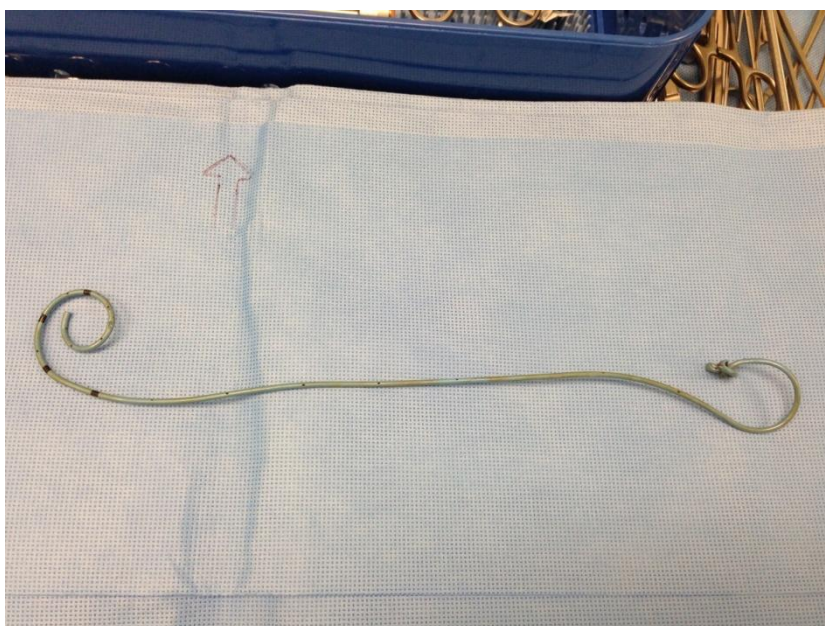


Figure 2.

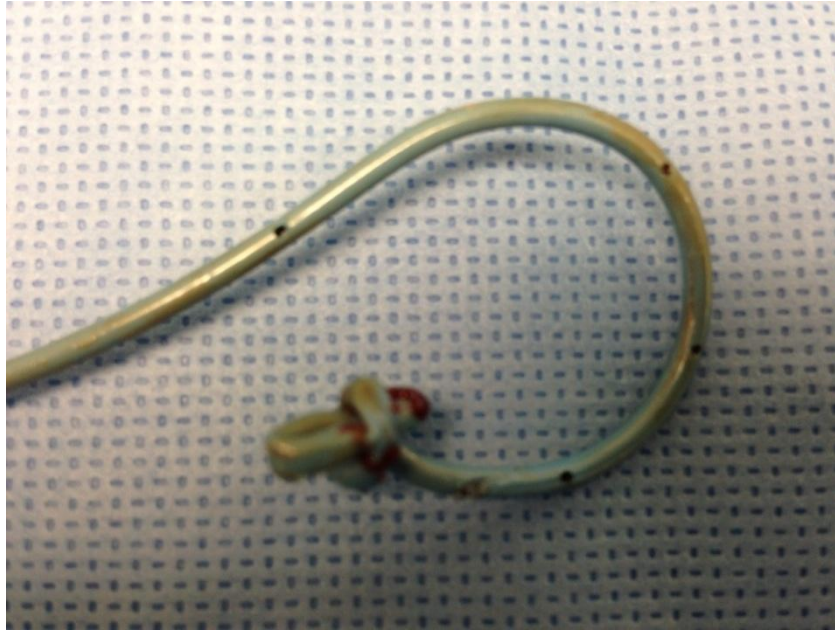


Figure 3.

stent was inserted. After observation, the patient recovered well and discharged the same day postoperatively.

DISCUSSION

The complications and consequences of indwelling ureteral stents include bladder storage voiding symptoms, flank pain, stent colic, vesicorenal reflux, malposition, haematuria, urinary tract infection, bacteriuria, fever, encrustation, inadequate relief of obstruction, stent migration, stent rupture, ureteral perforation, erosion and fistulisation (Saltzman B, 1988). One of the rare complications is stent knotting in different portions, proximal end knotting being the most common. Since the first report in 1989, only fourteen cases have been published in the international literature. The excess of tubing length in one of the extremities could be the main factor contributing to knotting (Baldwin DD et al., 1998), in addition to other factors such as the duration of stent remaining in the ureter, presence of obstructing stone and stent encrustation (Quek ML and Dunn MD, 2002). Management of such rare complication still operator dependent, including simple traction with delayed removal, removal with stiff guide wire assistance, ureteroscopy, open ureterotomy, and percutaneous removal. Holmium laser as a method of stone disintegration in our case was useful in order to get access to the knotted stent. Selection of the correct length of stent and assuring good position with x-ray

guidance during insertion and removal might help avoiding this complication.

REFERENCES

- Ahallal Y, Khallouk A, El Fassi M J, Farih MH (2010). Risk Factor Analysis and Management of Ureteral Double-J Stent Complications. *Rev. in Urol.*, 12(2-3), e147–e151.
- Baldwin DD, Juriansz GJ, Stewart S, Hadley R (1998). Knotted ureteral stent: A minimally invasive technique for removal. *J Urol.*, 159:2065–6.
- Picozzi S, Carmignani L (2010). A knotted ureteral stent: A case report and review of the literature. *Urology Annals*, 2(2), 80–82. doi:10.4103/0974-7796.65108
- Quek ML, Dunn MD (2002). Knot formation at the mid portion of an indwelling ureteral stent. *J Urol.*, 168:1497.
- Richards MM, Khalil D, Mahdy A (2011). Successful Treatment of Stent Knot in the Proximal Ureter Using Ureteroscopy and Holmium Laser. *Case Reports in Medicine*. 502191. doi:10.1155/2011/502191.
- Saltzman B (1988). Ureteral stents: Indications, variations and complications. *Urol. Clin. North Am.*, 15: 481–91.
- Zimskind PD, Fetter TR, Wilkerson JL (1967). Clinical use of long-term indwelling silicone rubber ureteral splints inserted cystoscopically. *J. Urol.*, 97:840–4.

