

*Full Length Research Paper*

# Morphometric analysis of the mental foramen in adult human mandible in saurashtra region

Ritika Patel<sup>1</sup>, \*Ridhdhish Patel<sup>1</sup>, Mital Patel<sup>2</sup>

<sup>1</sup>P.G.Student, Department of Anatomy, M.P.Shah Govt. Medical College, Jamnagar, India

<sup>2</sup>Professor & Head, Department of Anatomy, M.P.Shah Govt. Medical College, Jamnagar, India

Accepted 25 July, 2015

The aim of the study was to determine the most common position, size and shape of the mental foramen in population of saurashtra region of Gujarat, which may useful for the future surgical implications. The mental nerve leaves the mandible via the mental foramen. The intra osseous course of the mental nerve is of particular importance in dental surgery. To get effective nerve blocks and avoids post surgical neurovascular complications, morphology and morphometry of the mental foramen is essential. This study was conducted using 62 dried adult human mandible of unknown sex obtained from Department of Anatomy, M.P.Shah Govt. Medical College, Jamnagar, Gujarat, India. Morphology and Morphometry of mental foramen including size, shape and position of mental foramen were studied. The incidences of the accessory mental foramen were also studied. The findings indicated that most common position of mental foramen was position IV- the longitudinal axis of the second premolar for right side 25(40.32%) and left side 27(43.55%). The most common shape of the mental foramen was oval (79.03%). The accessory mental foramen was most commonly situated on right side 5(8.06%).

**Key words:** Mental Foramen (MF), Accessory Mental Foramen (AMF), morphometry, dental surgery, anatomical variations.

## INTRODUCTION

The mental foramen lies below either the interval between the premolar teeth, or the second premolar tooth, midway between the upper and lower borders of the body of mandible (figure 1) (Standing S et al., 2005). Variations in the position of the mental foramen had been reported by many authors in different ethnic groups (Green RM, 1987). Various shapes of mental foramen had also been noticed (Agarwal DR et al., 2011).

The mental nerve leaves the mandible via the mental foramen. It may extend anteriorly for 2–3 mm within the mandible before curving back to the mental foramen. The intra osseous anatomy of the mental nerve is of particular importance in dental implant surgery, the nerve may be

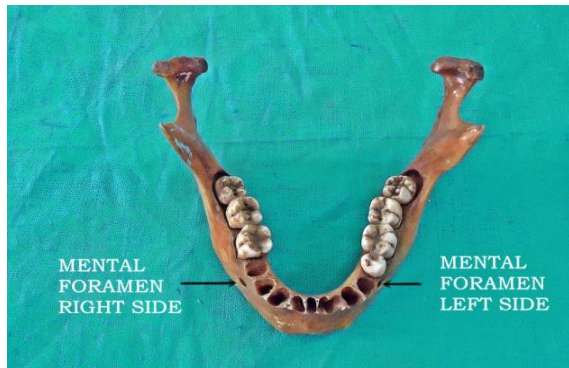damaged if the interforaminal area of the mandible is invaded during surgery or while harvesting block grafts from the symphyseal region (Standing S et al., 2005).

In order to obtain effective nerve block and to avoid post surgical neurovascular complications in the mental regions, attention should be paid to morphology and morphometry of the mental foramen (Rakhi Rastogi et al., 2012). Hence an attempt was made in present study to determine the most common position, size and shape of the mental foramen in population of saurashtra, Gujarat which may useful for the future surgical implications.

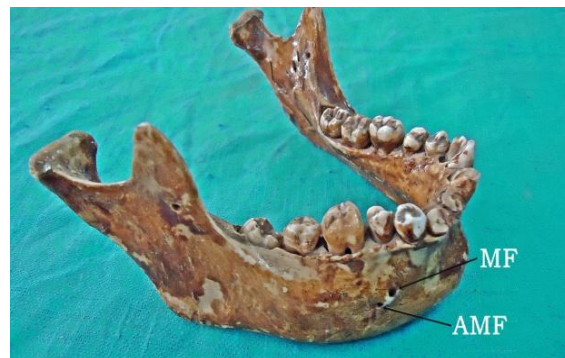## MATERIAL AND METHODS

62 dried adult human mandible of unknown sex obtained from Department of Anatomy, M.P.Shah Govt. Medical

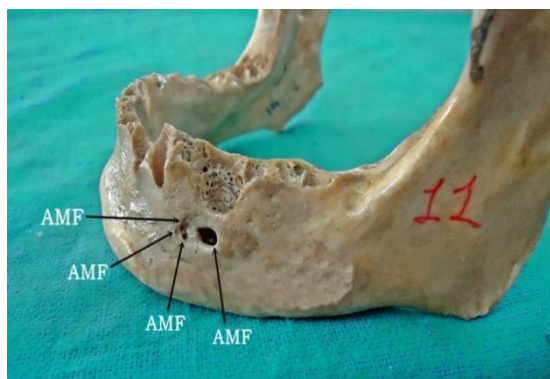
\*Corresponding Author E-mail: [ppritzs@gmail.com](mailto:ppritzs@gmail.com)



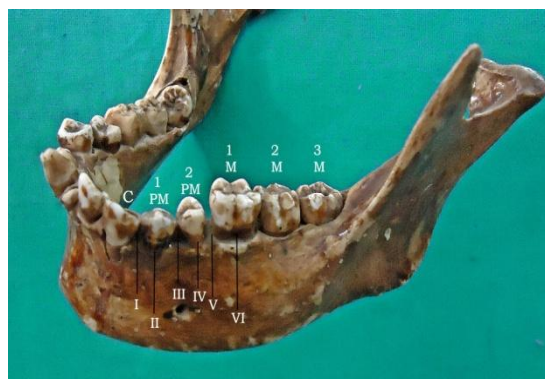
**Figure 1.** Position of mental foramen in relation to lower teeth.



**Figure 2.** Position of mental foramen (MF) and accessory mental foramen (AMF) in relation to lower teeth.



**Figure 3.** Left side of a mandible showing four mental foramina.



**Figure 4.** Position of mental foramen in relation to teeth (tebo & telford classification).

College, Jamnagar, India. Mandible with complete dentition and complete alveolar bridge were selected for the present study. Digital Vernier Caliper was used to measure dimensions of the mental foramen to analyse and examine the size, shape and position of mental foramen. The incidences of the accessory mental foramen were also observed (figure 2, 3). The positions of the mental foramen were measured with respect to the teeth, according to the Tebo and Telford classification (figure 4) (Tebo HG et al., 1950).

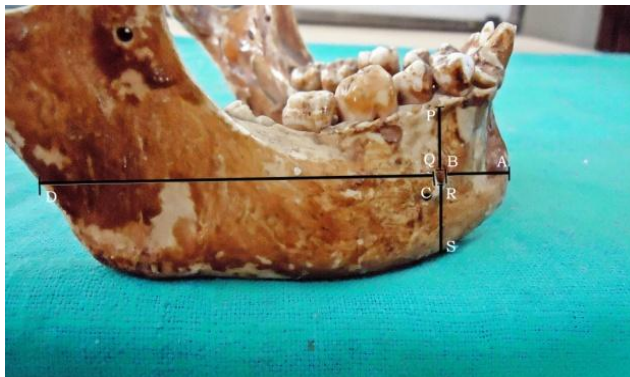
The positions of the mental foramen with respect to borders were also measured with the help of digital vernier calliper (figure 5). The size of mental foramen was calculated by measuring transverse and vertical diameters of mental foramen.

The transverse diameters were measured by using various parameters viz., the distance from the symphysis menti, the posterior border of the mandible, the base of the mandible and from the alveolar margins. (figure 5)  
 AD – The distance from the symphysis menti to the posterior border of the mandible.

AB – The distance from the symphysis menti to the anterior margin of the MF.  
 CD – The distance from the posterior margin of MF to posterior border of the mandible.  
 BC– The transverse diameter (TD) of the MF  
 The vertical diameters were measured by using the following parameters viz., (figure 5)  
 PS – The distance from the alveolar margin to the base of the mandible.  
 PQ – The distance from the alveolar margin to the superior margin of the MF.  
 RS – The distance from the inferior margin of the MF to the base of the mandible.  
 QR – The vertical diameter (VD) of the MF.  
 Statistical analysis was done to find out minimum and maximum incidences. The mean and standard deviation were also calculated.

**RESULTS**

The positions of the MF with respect to the teeth of the



**Figure 5.** Position of mental foramen and its size calculated by transverse and vertical measurement of mandible in relation to borders.

**Table 1.** Position of mental foramen in relation to lower teeth.

	MENTAL FORAMEN	I	II	III	IV	V	VI
RIGHT	Frequency	2	9	18	25	4	3
	%	3.22	14.52	29.03	40.32	6.45	4.83
LEFT	Frequency	1	9	17	27	3	3
	%	1.61	14.52	27.42	43.55	4.83	4.83

lower jaw were classified according to the method of Tebo HG et al., 1950. (figure 4)

I. The foramen which lay on a longitudinal axis which passed between the canine and the first premolar.

II. The foramen which lay on the longitudinal axis of the first premolar.

III. The foramen which lay on the longitudinal axis which passed between the first and second premolars.

IV. The foramen which lay on the longitudinal axis of the second premolar.

V. The foramen which lay on the longitudinal axis which passed between the second premolar and the first molar.

VI. The foramen which lay on the longitudinal axis of the first molar.

The analysis of present study showed that the most common position of mental foramen was position IV for both right sides 25(40.32%) and left sides 27(43.55%). Second most common position was position III for both right sides 18(29.03%) and left sides 17(27.42%), followed by position II for right sides 9(14.52%) and left sides 9(14.52%), position V for right sides 4(6.45%) and left sides 3(4.83%), position VI for right sides 3(4.83%) and left sides 3(4.83%), and position I for right sides 2(3.22%) and left sides 1(1.61%) (Table 1).

The average distance of mental foramen from the symphysis menti of mandible (AB) was  $25.75 \pm 2.37$  on right side and  $25.65 \pm 1.9$  on left side. The average

distance of mental foramen from posterior border of ramus of mandible (CD) was  $65.15 \pm 5.38$  on right side and  $65.09 \pm 4.34$  on left side. From the alveolar margin mental foramen located at an average distance (PS) of  $27.98 \pm 3.14$  on right side and  $27.46 \pm 3.95$  on left side. The average distance of mental foramen from base of mandible (RS) was  $13.38 \pm 1.79$  on right side and  $13.32 \pm 1.92$  on left side. An average transverse diameter (BC) was  $3.08 \pm 0.60$  on right side and  $3.15 \pm 0.67$  on left side whereas vertical diameter (QS) was  $2.57 \pm 0.43$  on right side and  $2.72 \pm 0.63$  on left side. (Table 2, 3)

The present study showed that shape of mental foramen of mandible was oval in 79.03% cases and rounded in 19.35% cases on the right as well as left side. The present study also showed that accessory mental foramen was located unilaterally in 4(6.45%) and bilaterally in 1 (1.61%) cases. Frequency of unilateral accessory mental foramen was more on right side 5(8.06%) than left side 1(1.61%) of the mandible.

## DISCUSSION

The location of mental foramen is clinically important for anaesthetic block of surgery in the outer premolar mandibular region. The present study provides new data for the position of mental foramen in an adult saurashtra population. Clinically, the mental nerve bundle that emerges

**Table 2.** Statistical analysis of position of mental foramen and its size in relation with borders of right side. MIN- minimum, MAX-maximum, SD- standard deviation.

<b>PARAMETERS (mm) (Right side)</b>	<b>AD</b>	<b>AB</b>	<b>CD</b>	<b>BC</b>	<b>PS</b>	<b>PQ</b>	<b>RS</b>	<b>QS</b>
MIN	78.06	17.52	52.84	2.09	21.75	5.57	8.68	2.02
MAX	111.7	31.61	81.89	4.82	36.55	20.8	17.95	4.05
MEAN	93.98	25.75	65.15	3.08	27.98	12.01	13.38	2.57
SD	6.22	2.37	5.38	0.6	3.14	2.85	1.79	0.43

**Table 3.** Statistical analysis of position of mental foramen and its size in relation with borders of left side. MIN- minimum, MAX-maximum, SD- standard deviation.

<b>PARAMETERS (mm) (Left side)</b>	<b>AD</b>	<b>AB</b>	<b>CD</b>	<b>BC</b>	<b>PS</b>	<b>PQ</b>	<b>RS</b>	<b>QS</b>
MIN	79.98	21	53.45	2.04	20.69	4.07	8.95	2.02
MAX	105.1	28.6	76.31	5.02	33.97	17.69	18.01	4.52
MEAN	93.89	25.65	65.09	3.15	27.46	11.42	13.32	2.72
SD	4.59	1.9	4.34	0.67	3.95	2.65	1.92	0.63

from the foramen may get injured during surgical procedures with resulting paraesthesia or anaesthesia along its sensory distribution (Phillips JL et al., 1990).

Anatomically, the mental foramen is the opening of the mental canal. Mental foramen is most commonly situated between the apices of the first and second lower premolar (Sinnathamby CS, 1999). Although this was in accord with some European population, but this was an exception to other populations (Green RM, 1987; Phillips JL et al., 1990; Al Jaser et al., 1998; Ari et al., 2005; Shankland, 1994; Ilayperuma et al., 2009). Racial variation in the position of the mental foramen was clearly demonstrated. However, in present study most common position of mental foramen was situated on the longitudinal axis of the second premolar followed by the longitudinal axis which passed between the first and second premolars. The most common position of mental foramen in present study was in agreement with previous studies on the Sri Lankan population (Ilayperuma et al., 2009), central Indian (Rastogi R et al., 2011), south Gujarat population (Agrawal DR et al., 2011), north Indians (Budhiraja V et al., 2013) and south Indians (Udhaya K et al., 2013).

During the early prenatal life mental foramen is located in the alveolar bone between the primary canine and first molar. Therefore, it is speculated that positions other than the most common ones are due to a lag in prenatal development (Kjaer I, 1989).

The mean transverse diameter (TD) of mental foramen in present study was  $3.08 \pm 0.60$  on right side and  $3.15 \pm 0.67$  on left side whereas vertical diameter (VD) was  $2.57 \pm 0.43$  on right side and  $2.72 \pm 0.63$  on left side. The mean

transverse diameter of present study was consistent with corresponding figure of 3.33 mm observed in south Gujarat (Agrawal DR et al., 2011). The results of present study was closed to those of Ogun O et al. (2002) did study on mandibles of people from turkey and found a mean Horizontal Diameter (HD) of 2.93 mm on the right side and 3.14 mm on the left side, and a mean VD of 2.38 mm and 2.64 mm on the right and left sides, respectively. In another study conducted by Singh R et al. (2010) only the HD was taken and the results showed the mean HD to be 2.79 mm on the right side and 2.57 mm on the left side, which was less than present study. Rastogi R et al. (2011) described that the horizontal diameter was  $4.57 \pm 0.19$  mm on the right side and  $4.61 \pm 0.17$  mm on the left side; VD was  $3.58 \pm 0.17$  mm on the right side and  $3.55 \pm 0.18$  mm on the left side, which was higher than the present study. Udhaya K et al. (2013) measured the average HD of the MF was  $2.28 \pm 0.71$  mm on the right side and  $2.95 \pm 0.68$  mm on the left side; the vertical diameter was  $2.86 \pm 0.83$  mm on the right side and  $2.52 \pm 0.87$  mm on the left side, which was less than present study.

From the symphysis menti, position of mental foramen at an average distance of  $25.75 \pm 2.37$  mm on right side and  $25.65 \pm 1.9$  mm on left side. Ilayperuma et al. (2009) observed the above distance was  $24.97 \pm 6.07$  mm on the right side and  $24.07 \pm 6.07$  mm on the left side in Sri Lankans. They also observed that the mean distance between the mental foramen and mandibular midline was varied among populations.

The present study showed that shape of mental foramen of mandible was oval in 79.03% cases and rounded

in 19.35% cases on the right as well as left side. This was in agreement with the results of Ilayperuma I et al. (2009), Agrawal DR et al. (2011), Udhaya K et al. (2013) and Budhiraja V et al. (2013). Whereas a result of present study was in contrast with those of Singh R et al. (2010) and Rastogi R et al. (2011), they found that round shape was more common than oval on the right sides as well as left sides.

The present study showed that accessory mental foramen was located unilaterally in 4(6.45%) and bilaterally in 1 (1.61%) cases. It was more frequently present at right side 5(8.06%) than left side 1(1.61%) of mandible which was similar to the study of Budhiraja V et al. (2013), observed that in 7 cases and was unilateral. Result of present study was in contrast to Singh R et al. (2010), observed that 8% AMFs on left side and 5% on right side.

## CONCLUSION

In present study majority of mandibles had oval shaped foramen lying on the longitudinal axis of the second premolar. The accessory mental foramen was most commonly present unilaterally right side. However, variations do exist in the position, shape, and size of mental foramen in different population groups. Study gave valuable information regarding the morphology and morphometry of mental foramen in population of saurashtra region, Gujarat. It is essential to be aware of the possibility of these anatomical variations while planning surgery in that region to avoid nerve damage and also to enable effective mental nerve block anesthesia.

## REFERENCES

- Agarwal DR, Gupta SB (2011). Morphometric analysis of mental foramen in human mandibles of South Gujarat. *People's J Sci Res.* 4:pp. 15-18.
- al Jasser NM, Nwoku AL (1998). Radiographic study of the mental foramen in selected Saudi population. *Danto maxillofacial Radiology.* 27(6): pp.341-343.
- Ari I, Kafa IM, Basar Z, Kurt MA (2005). The localization and anthropometry of mental foramen on late Byzantine mandibles. *Collegium Antropologicum.* 29(1): pp. 233-236.
- Budhiraja V, Rastogi R, Lalwani R, Goel P, Bose SC (2013). Study of Position, Shape, and Size of Mental Foramen Utilizing Various Parameters in Dry Adult Human Mandibles from North India. *ISRN Anatomy.* 1-5
- Green RM (1987). The position of the mental foramen: A comparison between the Southern (Hong Kong) Chinese and other ethnic and racial groups. *Oral Surgery, Oral Medicine, Oral Pathology.* 63(3): pp. 287-290.
- Ilayperuma I, Nanayakkara G, Palahepitiya N (2009). Morphometric analysis of the mental foramen in adult Sri Lankan mandibles. *Int J Morphol.* 27(10): pp. 19-24.
- Kjaer I (1989). Formation and early prenatal location of the human mental foramen. *Scand. J. Dent. Res.* 97(1): pp. 1-7.
- Oguz O, Bozkir MG (2002). Evaluation of location of mandibular and mental foramina in dry, young, adult human male, dentulous mandibles. *West Indian Med. J.* 51(1): pp. 14-16.
- Phillips JL, Weller RN, Kulild JC (1990). The mental foramen: Size, orientation and positional relationship to the mandibular second premolar. *J. Endod.* 16(5): pp. 221-223.
- Rakhi Rastogi, Virendra Budhiraja, Sathpathi DK, Sandeep Singh, Kranti Kumar Gour, Shema Nair (2012). Morphology and morphometry of the mental foramen in dry adult human mandibles from central India and their clinical correlation. *Eur. J Anat.* 16(1): pp. 22-26.
- Shankland WE (2012). The position of the mental foramen in Asian Indians. *J. Oral Implantol.* 20(2): pp. 118-123.
- Singh R, Srivastav AK (2010). Study of position, shape, size and incidence of mental foramen and accessory mental foramen in Indian adult human skulls. *Int. J. Morphol.* 28(4): pp. 1141-1146.
- Sinnathamby CS (1999). *Last's Anatomy: Regional and Applied.* 10th Edn. Churchill Livingstone, Edinburgh. pp. 506.
- Standring S, Ellis H, Healy J, Johnson D, Williams A (2005). *Gray's anatomy: The anatomical basis of clinical practice: Infratemporal and pterygopalatine fossae and temporomandibular joint, chapter 31; 39th edition, Elsevier.* pp. 733-773
- Tebo HG, Telford IR (1950). An analysis of the variations in position of the mental foramen. *Anat. Rec.* 107: pp. 61-66.
- Udhaya K, Saraladevi KV, Sridhar J (2013). The Morphometric Analysis of the Mental Foramen in Adult Dry Human Mandibles: A Study on the South Indian Population; *J. Clin. Diagn. Res.* 7(8): pp. 1547-1551