

Full Length Research Paper

The modulatory effect of *Cochlospermum tinctorium* a rich aqueous root extract on liver damage induced by carbon tetrachloride in rats

E. U. Etuk^{1*}, B. M. Agaie², M. J. Ladan³ and I. Garba¹¹Department of Pharmacology, Usmanu Danfodiyo University, Sokoto, Nigeria.²Department of Veterinary Physiology and Pharmacology, Usmanu Danfodiyo University, Sokoto, Nigeria.³Department of Biochemistry, Usmanu Danfodiyo University, Sokoto, Nigeria.

Accepted 08 March, 2011

The aqueous root extract of *Cochlospermum tinctorium* (CTR) was investigated for its phytochemical composition; acute oral toxicity and hepatoprotective effect on carbon tetrachloride (CCl₄) induced liver damage in rats. Phytochemical screening indicates the presence of alkaloids, tannins, cardiac glycosides, saponins, flavonoids, triterpenes, cyanogenic glycosides and volatile oils while steroids and anthraquinones were absent. Administration of 5000 mg/kg (body weight) of the extract orally did not produce any death in the rats within the observable period. The extract at 100 – 300 mg/kg (body weight) significantly and dose dependently reduced the levels of Alanine aminotransferase (ALT), Aspartate aminotransferase (AST) and Alkaline phosphatase (ALP) enzymes levels in the CCl₄-treated rats. The values of serum albumin, serum total protein and reduced glutathione in the extract treated groups of rats remained comparatively higher than its values in the CCl₄-treated group. The pretreatment of the rats with the extract produced a significant (P < 0.05) reduction in blood clotting time. The histopathological findings were in support of the biochemical changes recorded during the study. These results suggest that aqueous root extract of CTR possess hepatoprotective effect against CCl₄-induced liver damage in rats and the extract at 5000 mg/kg body weight appeared to be safe when administered orally.

Key words: *Cochlospermum tinctorium*, carbon tetrachloride, transaminases, hepatoprotective.

INTRODUCTION

Hepatic disorder is one of the major causes of death among the adult population globally. Increasing alcohol consumption has been implicated as one of the major causative factor of liver disease in developed countries (Kuppuswamy et al., 2003). The other important factors especially in the developing countries include ingestion of crude plant extracts and unhygienic living environment. In the absence of reliable drugs for the treatment of liver diseases in modern medicine, there are a number of medicinal plants recommended for the treatment of liver disorders (Sanmugapriya and Venkataraman, 2006). Many traditional remedies employ herbal drugs for the treatment of liver ailments (Rao and Mishra, 1998). The

root of *Cochlospermum tinctorium*, a rich (CTR) was reported as the part of the plant most frequently used locally to treat liver diseases (Togola et al., 2005).

CTR is a shrub of 1 - 3 m tall, with a large panicle flowers and alternate lobed leaves that withered away during the dry windy season leaving the leafless stem. The plant is widely distributed throughout the savannah areas of west and central Africa particularly in the northern states of Nigeria, Niger, Mali and Senegal (Togola et al., 2005). The local names of this plant include: Belge or Kukur in Hausa, Samara Kayna in Zarma, Yarudi in Fulani and N'tiribara in Bambara. The rootstock yields a yellow dye which is used in Nigeria to colour butter and is capable of staining the mouth when chewed. In Niger Republic, apart from its medicinal use in treating jaundice, women utilize the root as a sauce in cooking. The plant is listed in third position on the inventory of traditional African hepatoprotective remedies (Abondo, 1990). Although

*Corresponding author. E-mail: etuk2005@yahoo.co.uk. Tel.: +2348054693770. Fax: +23460231514.

CTR is widely used as a local remedy for liver diseases; empirical data is lacking to support its efficacy or safety. The present study examined the phytochemical constituents, acute toxicity and hepatoprotective effect of CTR aqueous root extract using carbon tetrachloride intoxicated rats as experimental model.

MATERIALS AND METHODS

Collection and extraction of plant materials

The parts of CTR were collected from the plateau surrounding Gaya local government area in Niger -Republic in the month of February 2006. The plant was identified by Prof. B. L. Aliero of the Botany Department, Usmanu Danfodiyo University, Sokoto, Nigeria and a voucher specimen (No. DIC T – 06) deposited at the Botany Herbarium.

The fresh root of the plant was air-dried to a constant weight. The dried material was ground using mortar and pestle to a dry powder. One hundred grams of the powder was dissolved in 500 mls of distilled water. The mixture was constantly stirred for 10 minutes and then allowed to remain for 48 h. The extract was then filtered, concentrated in an aeration Oven at a temperature of 45°C to a deep brown solid residue (14.7%, w/w). The required concentrations of the extract were subsequently prepared in distill water and used for the experiments.

Experimental animals

Male wistar rats weighing 200 – 250 g, age 10 - 16 weeks were used in this study. The animals were housed in clean polypropylene cages, fed with commercial rat chow and given free access to water. They were maintained in the animal house of the Pharmacology Department, Usmanu Danfodiyo University, Sokoto, Nigeria under a well ventilated natural condition for 2 weeks before the start of the experiment. Permission from the Departmental ethical committee for laboratory use of animals was duly obtained before the animals were put into use.

Chemicals

The chemicals used in this study include; Carbon tetrachloride (Sigma, USA), 2, 4-dinitrophenyl hydrazine (IPAC, UK) and Silymarin (Sigma Chemical Company, USA) purchased from a local chemical distribution company. AST and ALT kits obtained from Randox Laboratory, UK. Others were potassium chloride, phosphate buffer and caffeine obtained from the Department of Pharmacology, UDUS. All the chemicals were of analytical grade.

Phytochemical screening

Standard screening test (Odebiyi and Sofowora, 1979) was used in screening the extract for different constituents. The aqueous root extract was evaluated for the presence of alkaloids, tannins, saponins, cardiac glycosides, cyanogenic glycosides, flavonoids, volatile oils, steroids, anthraquinones and triterpenes.

Acute toxicity test

The Lork (1983) method was used. Thirty in bred male rats weigh-

ing 200 - 250 g were randomly selected and divided into six groups for use in this experiment. The rats in groups 1 - 5 were administered with 1000, 2000, 3000, 4000 and 5000 mg/kg (body weight) of the extract respectively while those in group 6 received the equivalent volume of distilled water. The administrations were done through oral route using a stomach tube. Thereafter the animals were allowed to eat and drink freely, and observed over a period of 48 h for signs of toxicity or death.

Animal treatment

Thirty six in bred rats weighing 200 – 250 g were randomly selected and distributed into six (6) groups (n = 6). The rats in group A which served as control were fed with growers mash and given distilled water only. Group B rats received only 0.5 ml/kg body weight of CCl₄ in 1.0 ml of olive oil intraperitoneally (i.p) to induce hepatotoxicity (Goknur et al., 2000). Those in groups C, D and E were pretreated with 100, 200 and 300 mg/kg body weight respectively of aqueous root extract of CTR orally for 7 days before induction of hepatotoxicity with CCl₄ on the 8th day. The animals in group F received Silymarin (25 mg/kg b.w) per oral for 7 days before induction of hepatotoxicity with CCl₄ on the 8th day. Twenty four hours after the hepatotoxicity induction, blood clotting time was assessed in the animals by using Lee et al. (1999) method. The tail of each rat was cut with surgical blade and the bleeding surface was intermittently cleaned with a white sheet of paper. The time taken for a definite blood clot to form was monitored and recorded in seconds using a stop clock. Thereafter, all the rats were anaesthetized with chloroform and sacrificed. Blood sample was withdrawn by cardiac puncture for biochemical analysis and tissue sample collected from the liver for histopathological examination. In the biochemical analysis, the serum transaminases (AST and ALT) levels were measured using the methods of Reitman and Frankel (1957). The alkaline phosphatase activity was estimated using the Randox Kit Colorimetric method. Doumas (1997) method was used to estimate the total protein and albumin in the serum. The tissue sample obtained from the liver was divided into two portions. The first portion was perfused with cold 0.86% KCl, homogenised and centrifuged to obtain post mitochondrial supernatant for estimation of reduced liver glutathione (Nard et al., 1987). The remaining portion was fixed with 10% formalin, stained with haematoxylin and eosin before the slide was examined under a microscope.

Statistical analysis

The results of biochemical analysis were expressed as mean ± standard error of mean (S.E.M). The control and treatment groups were compared by using one way analysis of variance (ANOVA). Further differences were assessed by Turkey-Kramer multiple comparison test. The level of significance was taken at probability less than 5%.

RESULTS

Extraction and percentage yield

From the extraction, a dry solid residue, brownish in colour, bitter to taste with an aromatic smell was obtained. The percentage yield was found to be 14.7%, w/w. Phytochemical screening indicates the presence of alkaloids, tannins, cardiac glycosides, saponins, flavonoids, triterpenes, cyanogenic glycosides and volatile oils.

Table 1. Effect of pre-treatment with CTR extract on blood clotting time, serum AST, ALT and ALP in CCl₄ induced hepatotoxicity in rats.

Group	Treatment	Clotting time (sec)	AST (IU/L)	ALT (IU/L)	ALP (IU/L)
A	Control	272.0 ± 6.9	39.2 ± 1.0	54.6 ± 0.8	126.6 ± 1.0
B	CCl ₄	616.6 ± 1.0	108.8 ± 1.5	121.8 ± 0.9	300.8 ± 1.2
C	CTR(100 mg/kg) + CCl ₄	479.6 ± 6.5	61.2 ± 1.0	88.6 ± 1.2	218.6 ± 4.1
D	CTR(200 mg/kg) + CCl ₄	338.3 ± 3.8	49.8 ± 0.2	89.3 ± 1.1	141.0 ± 0.9
E	CTR(300 mg/kg) + CCl ₄	292.6 ± 3.8	40.6 ± 0.9	54.4 ± 0.7	131.0 ± 2.1
F	Silymarin + CCl ₄	323.3 ± 5.1	60.0 ± 1.9	71.6 ± 1.2	119.5 ± 1.2
One-way ANOVA	F	4438.9	2724.5	3914.9	7284.9
	Df	35	35	35	35
	P	0.001	0.001	0.001	0.001

Values are mean ± SEM; n = 6 rats in each group. Comparison was between control vs. treatment groups; and then CCl₄-treated Vs CTR + CCl₄-treated groups. P < 0.05; all significant.

Table 2. Effect of Pre-treatment with CTR extract on serum total protein, albumin, and reduced liver glutathione in CCl₄ induced hepatotoxicity in rats.

Group	Treatment	STP (g/100 ml)	SA (mg/dl)	STB (g/dl)	GSH(mM/g tissue)
A	Control	6.9 ± 0.8	3.6 ± 0.9	1.6 ± 0.1	6.1 ± 0.1
B	CCl ₄	6.3 ± 0.9	3.2 ± 0.8	4.8 ± 0.0	1.4 ± 0.0
C	CTR(100 mg/kg) + CCl ₄	6.3 ± 0.7	3.6 ± 0.6	2.8 ± 0.0	2.9 ± 0.0
D	CTR(200 mg/kg) + CCl ₄	6.8 ± 0.8	3.4 ± 0.7	2.0 ± 0.0	4.1 ± 0.0
E	CTR(300 mg/kg) + CCl ₄	7.2 ± 0.6	3.8 ± 0.5	1.6 ± 0.0	4.9 ± 0.0
F	Silymarin + CCl ₄	6.7 ± 0.9	2.8 ± 1.2	2.8 ± 0.0	3.9 ± 0.0
One-way ANOVA	F	1.190	1.155	5241.6	9452.4
	Df	35	35	35	35
	P	0.3374	0.3540	0.001*	0.001*

Values are mean ± SEM; n = 6 rats in each group. Comparison was between control vs. treatment groups, and then CCl₄- treated vs CTR + CCl₄-treated groups. With P < 0.05; * significant.

Acute toxicity test

The oral administration of 1000, 2000, 3000, 4000 and 5000 mg/kg body weight of aqueous root extract of CTR did not cause any death in the rats during the 48 h observed.

Animal treatment

Administration of 0.5 ml/kg body weight of CCl₄ to wistar rats in group (B) produced significant changes in the biochemical parameters when compared to the control group (A). The liver transaminases (ALT and AST), alkaline phosphatase (ALP) and serum total bilirubin (STB) levels were significantly elevated (P < 0.05), while the serum total protein (STP), serum albumin (SA), and Reduced liver glutathione (GSH) levels were reduced in the CCl₄ - treated rats as compared to the control group (Tables 1 and 2). The reduction in the protein levels was however not significant. Pretreatment of the rats in groups C, D and E with 100, 200, and 300 mgkg⁻¹ (body weight) of the

extract respectively produced a significant reduction in the levels of ALT, AST and ALP as compared to its values in the carbon tetrachloride treated group (B) (Table 1). The values of SA, STP and GSH in the extract treated groups remained comparatively higher than that of the CCl₄ - treated group (Table 2) . The effect of the extract on the biochemical parameters was dose dependent. The highest effect was produced by 300 mg/kg (body weight) of the extract. The pre-administration of 25 mg/kg body weight of Silymarin to the rats before induction of hepatic damage with CCl₄ also minimized the derangement of the biochemical parameters in the animals. But the extract produced a better result at 300 mg/kg body weight than Silymarin. The results also showed a significantly (P < 0.05) prolonged clotting time for CCl₄-treated group compared to the control group. Pretreatment with the extract produced a dose dependent reduction in clotting time as compared to the untreated group B. The reduction in clotting time produced by the extract at 200 mg/kg body weight was statistically similar to that produced by pretreatment with 25 mg/kg body weight of Silymarin.

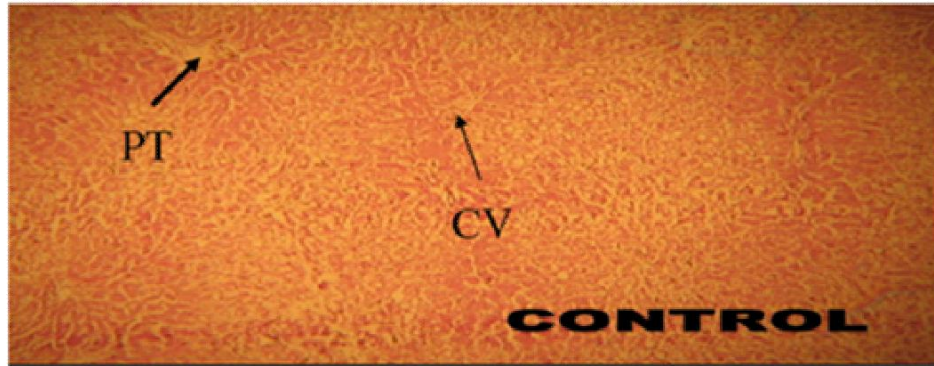


Plate 1. A cross section of rat liver showing normal architecture (x 50). **CV:** Central vein, **PT:** Portal Tract.

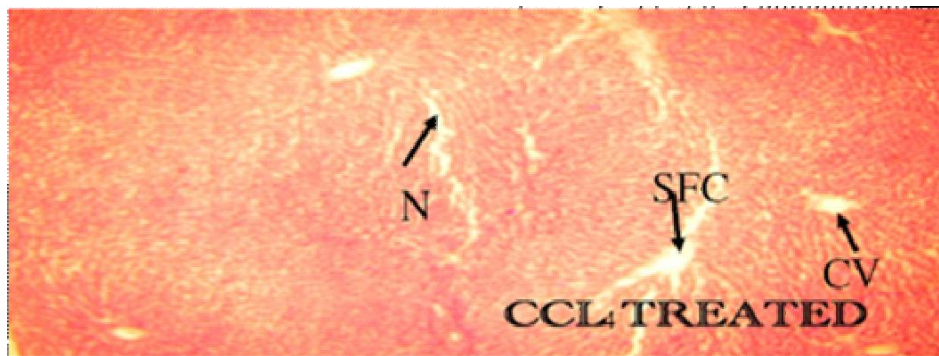


Plate 2. CCl₄ treated liver section showing Severe Fatty Change (SFC) and Necrosis (N) (x 50).

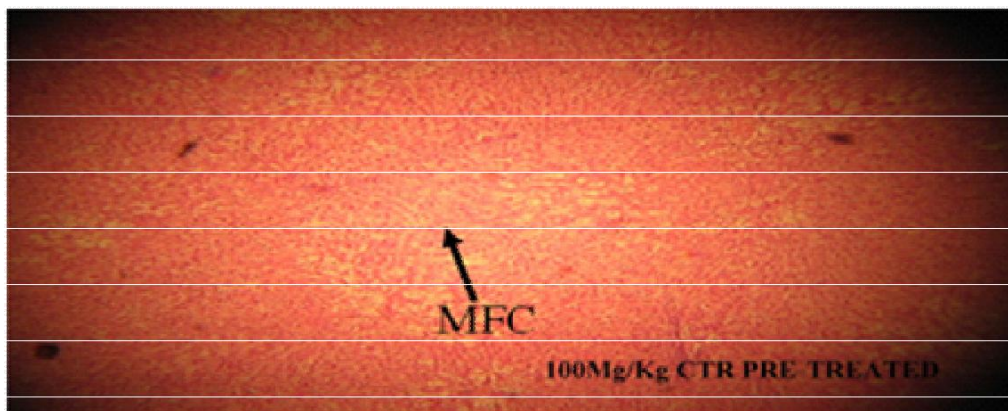


Plate 3. 100 mg/kg CTR Pretreated liver section showing Mild Fatty Change (MFC).

Histopathological analysis

Administration of CCl₄ produced visible hepatic lesions in form of severe fatty changes and necrosis in the rats when compared to the control group (Plates 1 and 2).

Pretreatment of the rats in group C, D and E with 100, 200 and 300 mg/kg (body weight) of extract progressively limit the necrotic lesions produced in the liver sections by CCl₄ as seen in Plates 3, 4 and 5. Silymarin administration also reduced the hepatic cellular damage (Plate 6).

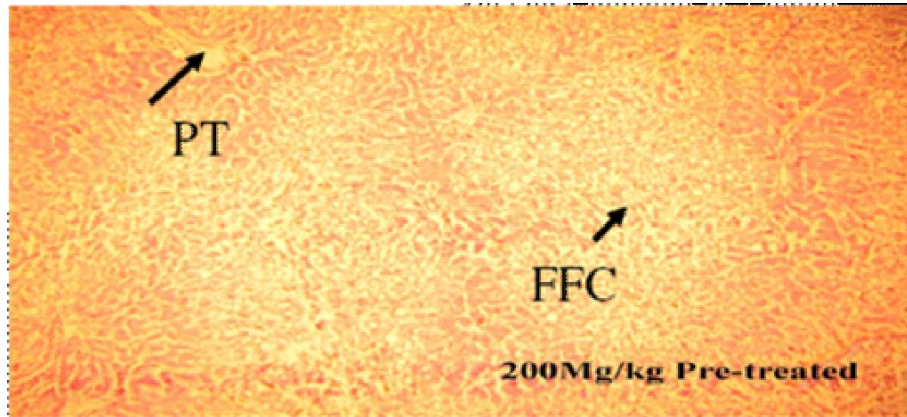


Plate 4. 200 mg/kg CTR Liver section showing Focal Fatty Change (FFC).

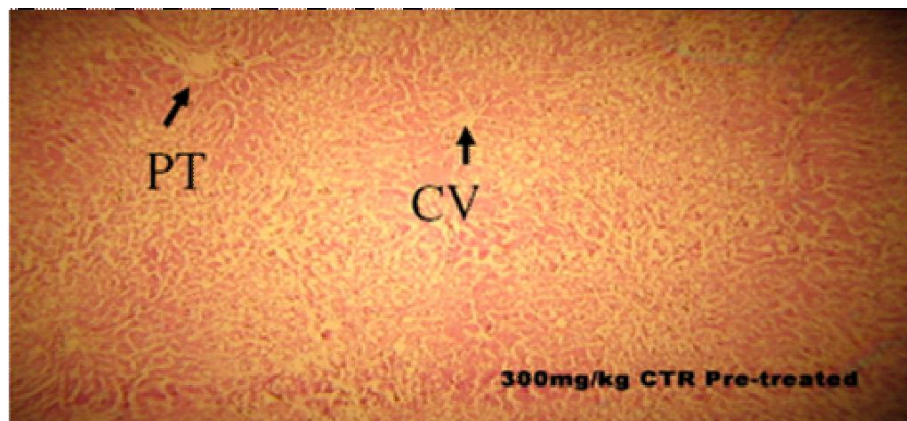


Plate 5. 300 mg/kg CTR pretreated liver section showing No fatty.

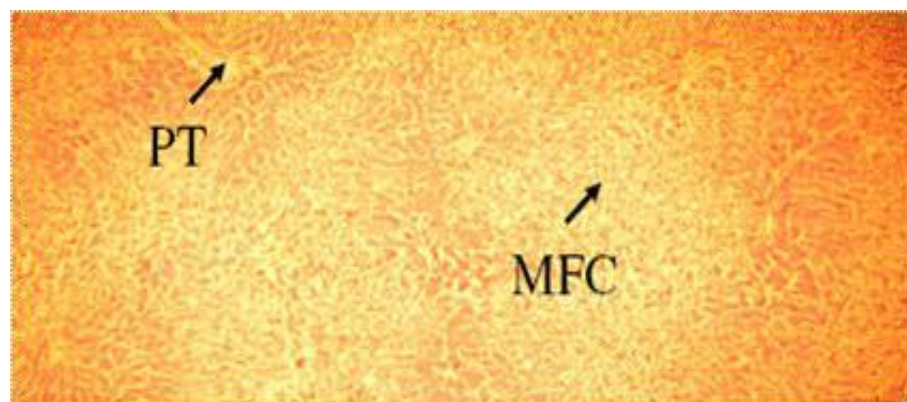


Plate 6. 25 mg/kg Silymarin pretreated liver section showing Mild Fatty Change (MFC).

DISCUSSION

The result of the present study has shown that, the median lethal dose (LD₅₀) of aqueous root extract of CTR is greater than 5000 mg/kg body weight of the rat when

administered orally. Therefore the extract may be considered safe for oral administration. According to the European Chemical Industry Ecology and Toxicology guideline, a compound with a median lethal dose of above 2 g/kg may be likely non-toxic. However, a further study is

required to determine the actual LD₅₀ of the extract. Administration of a single dose of carbon tetrachloride successfully induced hepatotoxicity in the rats that was evidenced by changes in the clotting time, biochemical parameters as well as histopathological lesions in the liver. Chemical induction of hepatic damage with CCl₄ in rats has been previously demonstrated by other workers (Rao et al., 2006; Abdel-Hamid, 2006).

CCl₄ is metabolized by the Cytochrome P-450 system in the liver into a highly reactive trichloromethyl free radical that binds to biological membranes initiating lipid peroxidation, disturbed calcium homeostasis and finally causing cell death (Rechnagel et al., 1989). In this study, CCl₄ administration significantly elevated serum ALT, AST and STB with a concomitant reduction of STP and GSH. These observations are indicators of hepatic cell damage and in accordance with the report of Venukumar and Latha (2002).

The liver is the primary site for the synthesis of plasma proteins; hepatic injury will cause a decrease in serum albumin and total protein concentrations. However the decreases were not significant probably because the liver damage was acute and the reserve capacity of the liver couple with the relative long half-life of these proteins did compensate for the damage. The elevation in bilirubin level observed in the CCl₄-treated rat group may be as a result of intrahepatic canaliculi obstruction produced by the hepatic cells inflammation. Pretreatment with the extract in all doses as well as with the standard drug Silymarin significantly ($P < 0.05$) reduced these liver enzyme levels dose dependently, showing that extract has hepatoprotective action. It is possible that, the hepatoprotective activity exerted by this extract may be related to the antioxidant effect of the phytochemical compounds found in the extract. Tasaduq et al. (2003) reported that, the antioxidant activity or inhibition of the generation of free radicals is important in the protection against CCl₄-induced liver lesion. Chemical compounds such as flavonoids and tannins have been reported to exert antioxidant activity by scavenging free radicals that cause lipid peroxidation (Zhao et al., 2007).

The phytochemical analysis of CTR root extract in this study indicates the presence of alkaloids, tannins and cardiac glycosides as the major constituents. Similarly, the present result also shows that the Reduced liver glutathione (GSH) level was significantly reduced in the CCl₄-treated rats but a near to normal level was preserved in the group of rats pretreated with 300 mgkg⁻¹ body weight of the extract. Glutathione is a critical determinant of tissues susceptibility to oxidative damage and the depletion of hepatic Reduced glutathione has been shown to be associated with an enhanced toxicity to chemicals including CCl₄ (Hewawasam et al., 2004).

The extract administration further significantly reduced the blood clotting time in the rats following hepatotoxicity induction with CCl₄. This further proves the ability of the extract to prevent hepatic damage and preserves hepatic

functions. The liver is the principal site for the synthesis of all circulating proteins apart from gamma-globulins, which are produced in the reticuloendothelial systemic. Blood coagulation requires the presence of these specialized proteins synthesized in the liver and transported in the blood circulation. Histopathological findings indicate that pretreatment with the extract offered protection to the hepatocytes from damage induced by CCl₄. Only mild fatty changes in the hepatic parenchymal cells was observed which collaborates with the results obtained in the biochemical parameters.

Conclusion

The results of the current study have shown that CTR aqueous root extract is safe and possesses hepatoprotective activity against CCl₄-induced liver cells damage in rats. This provides evidence that support the traditional use of the plant extract in the treatment of liver diseases.

ACKNOWLEDGEMENTS

The researchers are grateful to Prof. Rafindadi and Dr. Saadu both of the Department Histopathology, Ahmadu Bello University, Zaira, Nigeria for their assistance in carrying out the histopathological examinations.

REFERENCES

- Abdel-Hamid NM (2006). Diphenyl dimethyl bicarboxylate as an effective treatment for chemical-induced fatty liver in rats. *Afr. J. Biomed. Res.* 9 : 77-81.
- Abondo AF, Mbenkum, DT (1990). Ethnobotany and the medicinal plants of the Korup rainforest project area, Cameroon. Proceedings of International conference on traditional medicinal plants. Arusha, Tanzania, Feb 18-23. Editor, Mshigeni KE, Dares Salam Uni. Press. ISBN – 9976 60 2294. pp. 112-124.
- Doumas BT, Watson, W, Homer G. (1997). Albumin standards and the measurement of serum albumin with bromocresol green. *Clinica Chimica Acta.* 258(1) : 21-30.
- Goknur A, Didem D, Ender E, Fatma E, Erdem Y, Cemal C (2000). Hepatoprotective effect of Turkish folk remedies on experimental liver injury. *J. Ethnopharmacol.* 73 (1-2) : 121-129.
- Hewawasam RP, Jayatilaka PW, Pathirana C, Madduwa KB (2004) Hepatoprotective effect of *Epaltes divaricata* extract on carbon tetrachloride induced hepatotoxicity in mice. *Ind. J. Med. Res.* 120 : 30-34.
- Kerstin H, Kenne L, Rukunga G, Samuelsson G, Kofi-Tsekpo W (1990). Chemical characterization of pharmacologically active compounds from *Synadenium persiifolium*. Proceedings of International conference on traditional medicinal plants. Arusha, Tanzania, Feb 18-23. Editor, Mshigeni KE, Dares Salam Uni. Press. ISBN – 9976 60 2294. pp. 39-41.
- Kuppuswamy RG, Anbuganapathi V, Gokulakrishnan B, Raj Kapoor B, Jayakar H, Manian, S (2003). Effect of dried fruits of *Solanum nigrum* LINN against CCl₄ – induced hepatic damage in rats. *Biological and Pharmaceutical Bulletin* 26, 1618-1619.
- Lee J, Son KH, Chang HW, Do JC, Yang KY, Kang SS, Kim HP (1996). Haematological profile following chemical induced hepatotoxicity in rats. *Arch. Pharm Res.* 16: 25.
- Lork D (1983). A new approach to practical acute toxicity testing. *Archives of Toxicology.* 54(4): 275-287.

- Nard N, Gupta S, Sharma M, Khosia SN, Saini AS, Lai H (1987). Evaluation of enzymes in serum and cerebrovascular accidents. *Angiology*, 38 (10):750-755.
- Odebiyi OO, Sofowora EA (1979). Phytochemical screening of Nigerian Medical Plants – part 1. 2nd OAU/STRC. Inter-Africa Symposium on Trade Pharmacoeia and African Medicine Plants. Pub. 115-216.
- Rao GMR, Chandana P, Palpu Annie S (2006). Hepatoprotective effects of rubiadin, a major constituent of *Rubia cordifolia* Linn. *J. Ethnopharmacol.* 103(3): 484-90.
- Rao KS, Mishra, SH (1998). Antihepatotoxic activity of monomethyl fumarate isolated from *Fumaria indica* J. *Ethnopharmacol.* 60(3) : 207-213.
- Reitman, S., Frankel, S. (1957). A colorimetric method for the determination of serum glutamic oxalacetic and glutamic pyruvic transaminases. *Am. J. Clin. Path.* 28(1): 56-63.
- Sanmugapriya E, Venkataraman S (2006). Studies on the hepatoprotective and antioxidant actions of *Strychnos potatorum* Linn. seeds on CCl₄ - induced hepatic acute injury in experimental rats. *J. Ethnopharmacol.* 105(1-2) : 154-160.
- Tasaduq SA, Sing K, Sethi S, Sharma SC, Berdi KL, Singh. J, Jaggi JS (2003). Hepatocurative and antioxidant profile of HP-1, a polyherbal phytomedicine. *Human Experimental Toxicol* 22 (12): 639-645.
- Togola A, Diallo D, Dembele S, Barsett H, Paulsen BS (2005). Ethnopharmacological survey of different uses of seven medicinal plants from Mali, (West Africa) in the regions Diola, Kolokani and Siby. *J. Ethnopharmacol.* 1(1); 1-7.
- Venukumar MR, Latha MS (2002). Hepatoprotective effect of the methanolic extract of *Curculigo orchioides* in CCl₄ – treated male rats. *Int. J. Pharmacol.* 34 : 269-75.
- Zhao Y, Zhai D, Chen X, Yang J, Song X, Hui H, Yu Q, Xing Y (2007). Ketoprofen glucuronidation and bile excretion in carbon tetrachloride and alpha – naphthylisothiocyanate induced hepatic injury in rats. *Toxicol.* 230(1-2): 145-150.