

Full Length Research Paper

# Exposure to smoke extract of *Datura stramonium* leaf: Some of its effects on the heart, liver, lungs, kidneys and testes of male Sprague Dawley rats

Adekomi D. A.<sup>1\*</sup>, Tijani A. A.<sup>2</sup>, Adeniyi T. D.<sup>2</sup>, Musa A. A.<sup>1</sup> and Usman B.<sup>3</sup>

<sup>1</sup>Department of Anatomy, Faculty of Basic Medical Sciences, University of Ilorin, Ilorin, Nigeria.

<sup>2</sup>Department of Anatomy, College of Health Sciences, Osun State University, Osogbo, Nigeria. <sup>3</sup>Center for Anatomy and Human Identification, College of Life Sciences, University of Dundee, Dundee, Scotland, United Kingdom.

Accepted 16 May, 2019

Smoking has been recognized as a significant contributor to mortality. The aim of this study was to evaluate some of the toxic effects of smoke extract of *Datura stramonium* leaf on the heart, liver, kidneys and testes of male Sprague Dawley rats. A total of ten male Sprague Dawley rats weighing between 100 and 120 g were used for this study. The animals were randomly assigned into two (2) groups; A and B. Animals in group B (treatment group) were exposed to smoke from a completely burnt 0.74 g leaf extract of *D. stramonium*, wrapped in 0.5 g of sterilized cotton wool for 5 min, three times daily. The animals in group A (control group) were exposed to smoke from completely burnt 1.24 g of sterilized cotton wool with the same parameters as observed with the treatment groups. The duration of exposure was for five days. 3 h after the last exposure, all the animals were sacrificed by cervical dislocation. The heart, liver, lungs, kidneys and testes were carefully excised, blotted dry, and fixed in formol saline for histological analysis using Hematoxylin and Eosin (H and E) stain. Using the light microscope, it was observed that, the cytoarchitectural profiles of the studied organs were well preserved in the animals in the control group. However, several histological deviations were seen in the sections of the heart, liver, lungs, kidneys and testes of the animals in the treatment group. These deviations range from distortion and degeneration of the hepatocytes, reduction in the population of the germ cells and enlargement of the alveoli. These histological deviations indicated that the smoke extract of *D. stramonium* leaf has deleterious effects on the heart, liver, lungs, kidneys and testes of male Sprague Dawley rats and may be associated with structural damage to these vital organs.

**Key words:** Cotton wool, *Datura stramonium*, histological deviations, kidneys, liver, testes.

## INTRODUCTION

The medicinal plant *Datura stramonium* is often used as an analgesic plant in folklore medicine in the "Old world" (Zargari, 1989). The plant has also been used as a narcotic and local anesthetic drug in many societies (Schulman and Bolton, 1998; Abena et al., 2003; Arouko et al., 2003). In some nations, young people in quest for cheap hallucinate, uses its leaves by smoking for hallucination purpose in order to make them "high" (Schulman and Bolton, 1998). Some scientific investigations

have reported that *D. stramonium* extract is especially rich in alkaloids (Hasan and Kushwaha, 1987; Piva and Piva 1995).

The alkaloid content of *D. stramonium* has been emphasized by the phytochemical investigators dealing with the biochemical composition of various parts of the plant. Atropine, hyoscyamine and scopolamine (hyoscine) are the tropane alkaloids of all species of the genus *Datura* and their concentrations showed variations depending on species and on the part of the plant (Checke and Shull, 1985; Duez et al., 1985; Ren-sheng et al., 1985). Duke (1992a) presented data on concentration of total alkaloids in leaves and flowers of *D. metel* (Hindu datura), *D. stramonium* (Jimson weed) and *D. innoxia* (Thorn apple).

\*Corresponding author. E-mail: [alexquye@gmail.com](mailto:alexquye@gmail.com) Tel: +23480-3844-1671, +23480-7656-3746.

The emphasis on tropane alkaloids is due to their importance in pharmaceutical industry. Proteins, fats, fatty acids, reducing sugars, oxalates, nitrates and tannin are among the chemical entities that have been described in the plant (Duke, 1985; Hussein, 1985). Chlorogenic acid, an anti-histaminic, an allantoin, an immunostimulant (Duke, 1992b), Lectin agglutinin, a glycoprotein (Russel et al., 1997; Pla, 2003), gamma amino-butyric acid, a hypotensive and neuro-inhibitor (Friedman and Levin, 1989), are within the list of the active ingredients present in *D. stramonium*. Measurable amounts of 27 metal ions have also been detected (Williams and Rayson, 2003).

The heart is a muscular organ present in all vertebrates. It functions in the pumping of blood through the blood vessels in a repeated contracting rhythm (Heath, 1999). The heart of a vertebrate is made up of cardiac muscle known as the myocardium, an involuntary muscle tissue which is found only within this organ. The myocardium is the heart's muscular wall (Heath, 1999). It contracts to pump blood out of the heart and then relaxes as the heart refills with returning blood. Its outer surface is called the epicardium. Its inner lining is the endocardium (Heath, 1999).

The liver is the second-largest largest organ in the mammalian body. It has a peculiar macro- and micro-morphology. The micro-morphology consists of lobules and sinusoids that are lined with active phagocytes known as the Kupffer cells; central portal veins and hepatocytes plates that are closely associated with the terminal lymphatics and bile canaliculi (Webster and Webster, 1974; Lesson et al., 1988; Berne and Levy, 1998; Costanzo, 1998). These distinguishing morphological features enable the liver to carry out a wide range of essential functions such as filtration, secretory and excretory functions and processes. The hepatocytes have metabolic functions that deal with very crucial processes such as detoxification, deamination, transamination, removal of ammonia in the form of urea, biosynthesis and release of the non-essential amino acids and plasma proteins. Approximately 15% of the adult life erythropoietin is synthesized by the hepatic Kupffer cells and hepatocytes (Binkley, 1995; Griffin and Ojeda, 1996; Ganong, 1999).

The functional and structural unit of the kidneys is the nephron. Kidneys of the mammalian species show variations in the ratios of the cortical and juxtamedullary nephrons but have in common, a unique structural characteristic that is the presence of two capillary networks: the glomerular and the peritubular structures. The endothelial cells of the peritubular capillaries have endocrine activity, which is represented by synthesis and release of the erythropoietin hormone. The granular juxtaglomerular cells of the afferent glomerular arterioles as well as the agranular lacis cells in the junction between the afferent and efferent glomerular arterioles are the specific cells that are responsible for renin

synthesis and release (Ganong, 1999; Junqueira et al., 1998).

The testis, which is the major male reproductive organ, is responsible for sperm production. It is suspended in the bilateral compartments of the scrotal sac. Production of spermatozoa from stem cells of the testis is a complex process that requires about 64 days in human (Heller and Clermont, 1964) and about 48 to 53 days in rat (Clermont, 1972; Hilscher, 1964). The sertoli cells play a vital role in spermatogenesis (Sapori, 1986; Sharpe, 1993), whereas, leydig cells are the main source of androgen production (Al-Hazmi, 2005). Both types of cells can be adversely affected by toxins and chemical drugs (Spielman, 1998; Papadakis, 1999). Also, an alteration in the functional integrity of these cells may lead to a deleterious compromise in the hormonal balance, or may disturb the process of spermatozoa development and may ultimately cause impaired male fertility (Monsees, 2000, 2001).

These vital organs have the capability of carrying out several essential functions in the body and which if compromised in any form and/or way, may be absolutely deleterious to the body.

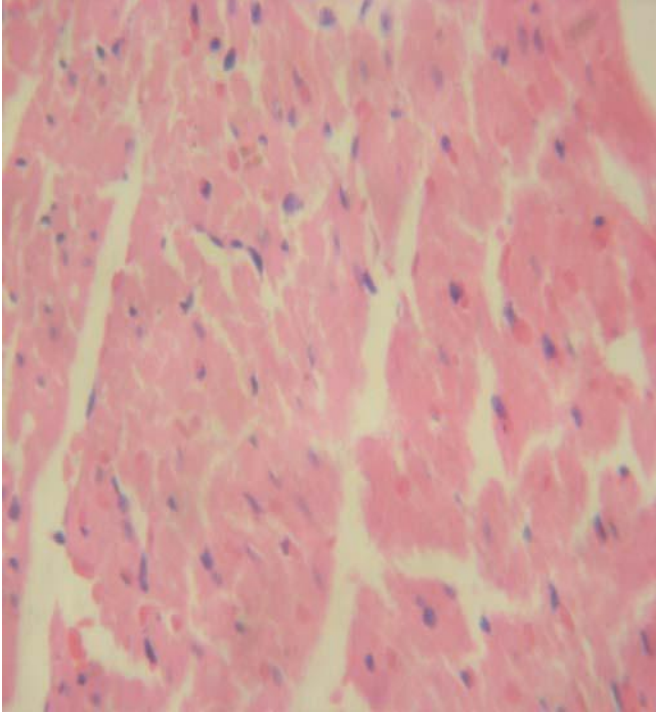
This study was done on animal models because it is not ethical and practical to perform such an investigation with human subjects. The most suitable model to use is one which is closely related to humans. Keeping these points in view, the study was performed on male Sprague Dawley rats, as they are easy to breed and rear and they can as well be handled with ease. According to the U.S. Department of Health and Human Services (2004), the body produces antioxidants that helps repair damaged cells. Smokers have lower levels of antioxidants in their blood than do nonsmokers. Smoking is associated with higher levels of chronic inflammation, another damaging process that may result in oxidative stress.

The components of smoke are complex and vary considerably in relation to conditions of incomplete combustion, the combustion materials, temperature, circumstances and timing (Xie et al., 1998), and since smoking has been recognized as a major contributor to mortality in man, previous studies have confirmed the effects of tobacco and/or marijuana exposure on the brain, nervous system and the general body system (Dagher et al., 2001; DiChiara et al., 1992; Pfaus et al., 1990), but search for available literature on the effects of the smoke of *D. stramonium* on the heart, liver, lungs, kidneys and testes in laboratory animals is not available. Hence, the present study is aimed at investigating some of the effects of the smoke extract of *D. stramonium* leaf as a marker of toxicity on the histology of the heart, liver, lungs, kidneys and testes of male Sprague Dawley rats.

## **MATERIALS AND METHODS**

### **Collection of plant and preparation of plant extracts**

The sample of *D. stramonium* used was obtained from the botanical



**Figure 1.** Photomicrograph of the heart of the animals in the treatment group showing mild edema and destruction of myocardial fibers (H&E × 480).

garden of the University of Ilorin, Ilorin, Kwara State, Nigeria. Botanical identification was done at the Department of Plant Science, University of Ilorin, Nigeria. The leaves of the plant were air-dried under shade without sunshine. The dried plant material were weighed using Gallenkamp (FA2104A, England) electronic weighing balance and 0.74 g of the plant sample was later wrapped with 0.5 g of refined and sterilized cotton wool.

#### Animal care

This experimental investigation was done in accordance with the standard humane animal care as outlined in the “Guide for the care and use of Animals in research and teaching”, as approved by the Institute of Laboratory Animal Resource, National Research Council, DHHS, Pub. No NIH 86 – 23 (NIH, 1985). The study was carried out using 10 presumably healthy male Sprague Dawley rats weighing between 100 and 120 g. All the animals were housed in clean cages of dimensions 33.0 × 20.5 × 19.0 cm placed in well ventilated standard housing conditions (12 h light and 12 h darkness; temperature: 28 to 31°C; humidity: 50 to 55%) (Yakubu, 2008) and their cages were cleaned everyday. All animals were observed for illness, abnormal behavior and physical anomalies. The rats were fed with standard rat chow at a recommended dose of 100 g/kg as advised by the International Centre of Diarrhoea Disease Research, Bangladesh (ICDDR, B) daily. Drinking water was supplied ad libitum.

#### Experimental design

In this study, 20 male Sprague Dawley rats weighing between 100 and 120g were used. Two closed glass chambers of approximately

0.1 m<sup>3</sup> volume (38 × 88 × 30 cm) (Onarlioglu et al., 1999) was also used. In the upper surface of the chambers, an opening of 1 cm was made (Onarlioglu et al., 1999). The chambers were designated as A and B respectively. The animals in group B were placed in chamber B and were exposed to smoke extract of *D. stramonium* leaf by inhalation (0.74 g leaf of *D. stramonium* wrapped with 0.5 g of refined and sterilized cotton wool for 5 min three times daily; 7am, 10am, and 1pm) for 5 days. The animals in group A were placed in chamber A and were exposed to the same amount of refined sterilized cotton wool three times daily (7am, 10am, and 1pm) for 5 days.

#### Animal sacrifice

Three hours after the termination of investigation, the animals were sacrificed by cervical dislocation (Adekomi, 2010), but the heart, liver, kidneys and testes were carefully excised from the animals, rinsed in cold sucrose solution and blotted dry with filter paper. The liver, lungs and heart were fixed in separate specimen bottles containing 10% formol-saline while the kidneys and testes were quickly transferred into a specimen bottle containing Bouin’s fluid. Thereafter, the fixed specimens were removed from the fixatives in order to process for further histological analysis.

#### Histological parameters

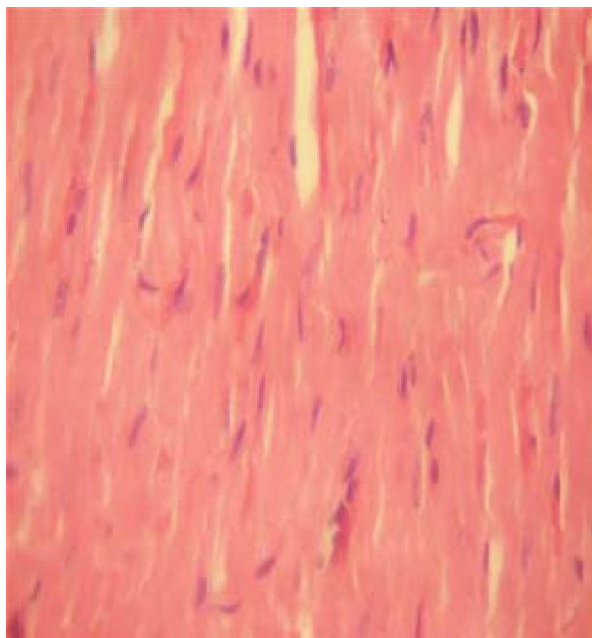
Histological studies on the heart, liver, lungs, kidneys and testes were done according to the procedures described by Disbrey and Rack (1970) and Drury and Wellington (1967). The sections were subjected to Hematoxylin and Eosin (H and E) staining procedures and the histological examination was done with the aid of the Olympus binocular light research microscope (XSZ-107BN, No. 071771). The permanent photomicrographs of each slide were recorded with a Kodak digital camera (Kodak Easyshare C183) for subsequent histological analysis.

## RESULTS

No morphological alterations were observed in the morphology of the heart, liver, lungs kidneys and testes of the animals in both groups (A and B) sacrificed (3 h) after the termination of experimental procedure. The excised heart, liver, lungs, kidneys and testes of the animals in both groups appeared morphologically normal. Histological assessment of the heart of the animals in the treatment group showed significant abnormal alteration in the histological profile when compared with that of the animals in the control group. Some of the histological deviations include; marked edema and destruction of myocardial fibers (Figures 1 and 2).

The histological profile of the kidneys section of the animals in the treated group exposed to the smoke extract of *D. stramonium* leaf showed significant degenerative changes. In the renal cortex, there was shrinkage of the glomerulus and progressive death of the cells in the epithelial lining of the tubular system of the kidneys (Figures 3 and 4).

The histological outline of the lungs of the animals in the treatment group revealed significant cytoarchitectural alteration and/or disruption. Though the smooth muscle



**Figure 2.** Photomicrograph of the heart of the animals in the control group (H&E x 480).

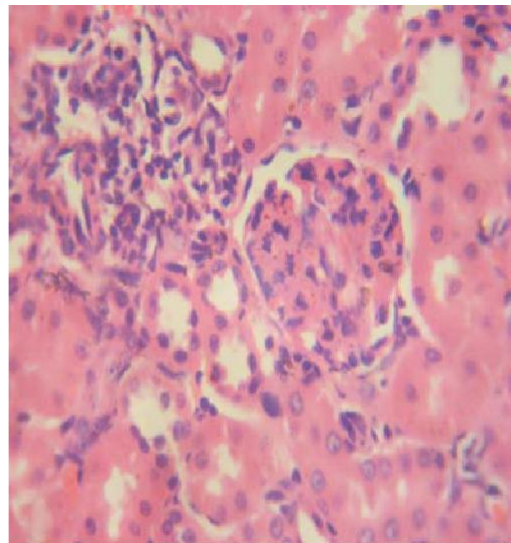
layer of the bronchi was preserved, there is still an enlargement of the alveoli and the alveoli sacs (Figure 5 and 6).

The histological outline of the liver section in treatment group does not conform to normal histological profile. Some of the histological alterations observed include degeneration, and progressive death of the hepatocytes, and occlusion of the central portal vein. Using a stereological grid (Caroline et al., 2003), it was also observed that the populations of the sinusoidal lining cells are few and scanty (Figure 7 and 8).

Sections of the testes of the animals in the treatment group revealed histological disruption and cellular derangement such as degeneration of the germ cells in the seminiferous tubules and also the degeneration of the leydig cells. Other effects such as cytoarchitectural distortions and vacuolations are evident in the section of the testes of the animals in the treatment group (Figure 9).

## DISCUSSION

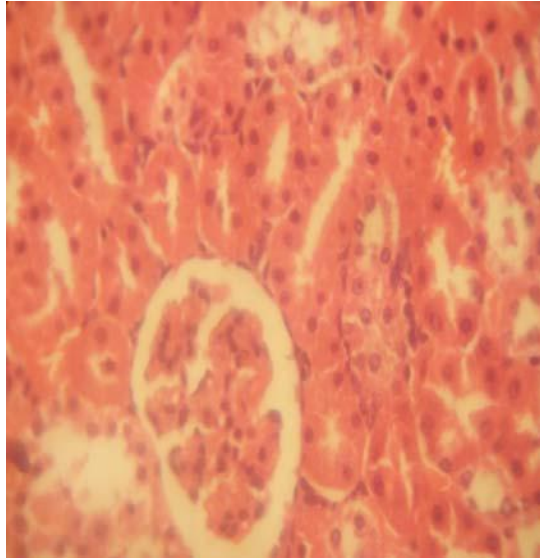
Several scientific literatures have discussed some of the effects of aqueous and ethanolic leaf extracts of *D. stramonium* on the laboratory animals (Gidado et al., 2001; Guharov and Barajas, 1991; Anozie, 1986). However, there is dearth of scientific literature on the effects of *D. stramonium* on the histology of the heart, liver, lungs, Kidneys and testes of male Sprague Dawley rats as a marker of toxicity.



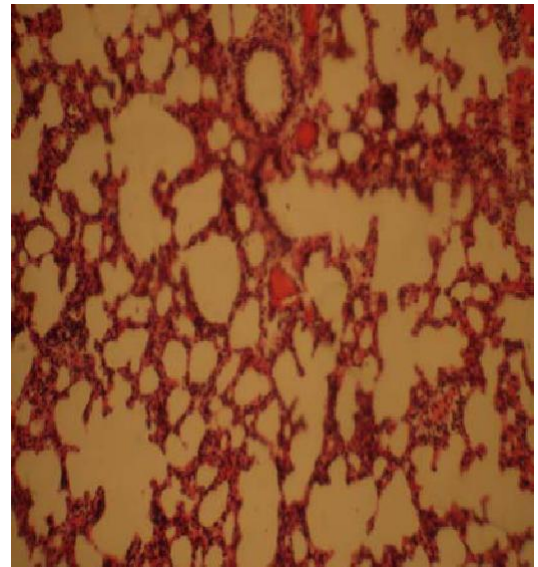
**Figure 3.** Photomicrograph of the Kidneys of the animals in the treatment group showing progressive death of the epithelial cells lining the convoluted tubules (H & E x 480).

In this investigation, we examined some of the effects of the smoke extract of *D. stramonium* leaf on the heart, liver, lungs, kidneys and testes of male Sprague Dawley rats. Evidence from this investigation through the use of the Olympus binocular light microscope (XSZ-107BN, No. 071771), showed that the smoke extract of *D. stramonium* leaf has adverse and severe effects on the histology of the heart, liver, lungs, kidneys and testes of male Sprague Dawley rats when compared with the control animals.

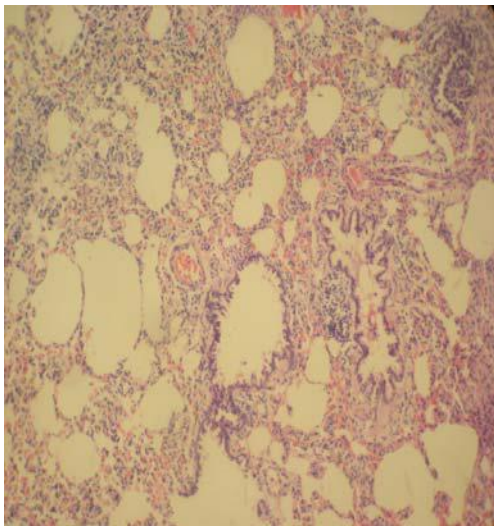
The massive enlargement of the alveoli and bronchiolar occlusion could have been a result of direct toxicity or could have resulted from transportation of toxic substances from other organs like the liver and kidneys to the lungs. The section of the liver, kidneys and testes obtained from the treatment group has disrupted histological organization compared with the control group. Some of the deleterious effects seen in the section of the liver obtained from the treatment group include degeneration and disruption of the hepatocytes, degeneration of the cells lining the bile ducts and occlusion of the central portal vein. With these histological abnormalities, the anatomical, physiological and biochemical functions of the liver could be compromised. It is known that the hepatocytes play a vital role in the proper functioning of the liver as the hepatocytes are the main functional cells of the liver. The hepatocytes frequently contain glycogen and the hepatocytes maintain a steady level of blood glucose. This is one of the main sources of energy for use by the body (Stevens and Lowe, 2005; Junqueira and Carneiro, 2003). A compromise in the integrity of the hepatocytes could lead to improper functioning of the liver.



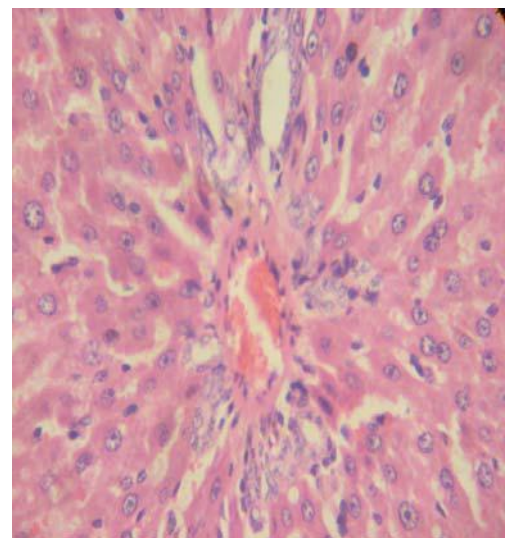
**Figure 4.** Photomicrograph of the Kidneys of the animals in the control group (H&E x 480).



**Figure 6.** Photomicrograph of the lungs of the animals in the control group (H&E x 480).



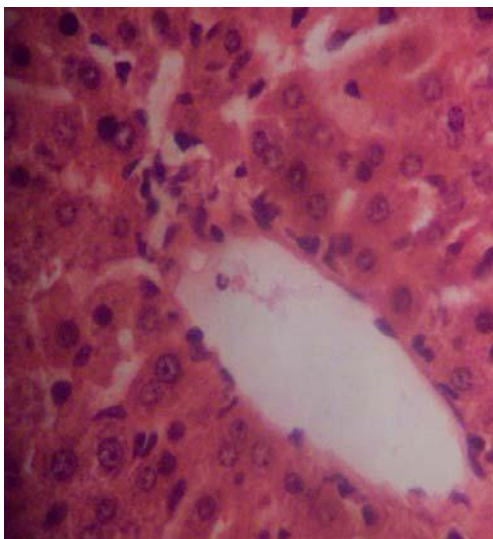
**Figure 5.** Photomicrograph of the lungs of the animals in the treatment group showing enlarged alveoli and alveoli sacs (H&E x 480).



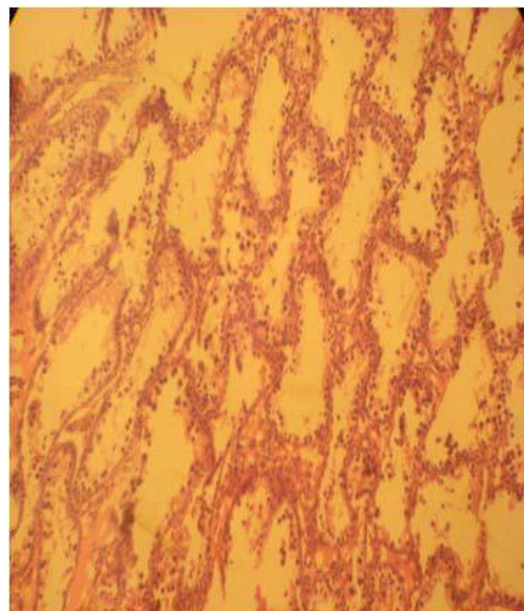
**Figure 7.** Photomicrograph of the liver of the animals in the treatment group showing distortion, degeneration and progressive death of the hepatocytes and also the occlusion of the portal vein. (H&E x 480).

The tubular structure of the renal cortex of the animals in the treatment group exposed to the smoke extract of *D. stramonium* leaf showed disruption in the histological make up of the organ. Varying degrees of vacuolation were also seen in the proximal convoluted tubules which may compromise the functional integrity of the brush border. These characteristics may lead to the retention of waste products of metabolism. Persistence of such abnormalities results into loss of the sensitive homeostatic functions of the kidneys (Stevens and Lowe, 2005). Kidneys are also the targets involved in

unavoidable side effects of so many drugs (Haschek and Rousseaux, 1998; Baylor and Williams, 1999; Forel, 2001; Mackinnon et al., 2003; Holland and Degruy, 1997). Renal damage has been reported as a side effect to the administration of many medications (Chang et al., 2001; Ono et al., 1998; Lord et al., 1999; McIntyre, 1998; Reginster et al., 1997). Such damage should reach a minimal accepted extent, as a side effect, at the end of experimentations aimed at determining the extent of



**Figure 8.** Photomicrograph of the liver of the animals in the control group (H&E x 480).



**Figure 9.** Photomicrograph of the testes of the animals in the treatment group showing distortion and gradual reduction in the population of the germ cells in the seminiferous tubules and also the degeneration of the leydig cells (H&E).

toxicity under specified conditions of frequency and duration of treatment.

Several abnormal histological alterations seen in the testes of the animals in the treatment group, ranges from degeneration and disruption of the germ cells lining the seminiferous tubules, and also the degeneration of the leydig cells. Reduction in the population of the germ cells was also seen in the histological profile of the testes obtained from the treatment group compared with the control group. The implication of this is that there is a reduction of viable sperms which may lead to infertility.

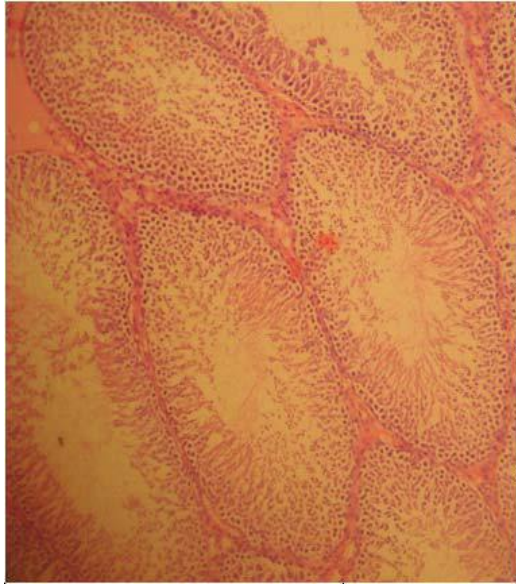
Degenerative changes have been scientifically reported to result in cell death. There are two types of cell death, namely, apoptosis and necrosis (Cohen, 1993; Vaux et al., 1994). These two types differs biochemically and morphologically (Bose and Sinha, 1994). Apoptosis is a non-inflammatory response to tissue damage characterized by a series of morphological and biochemical alterations (Sakkas et al., 1999; Sinha and Swerdloff, 1999; Shen et al., 2002; Grunewald et al., 2005). Apoptosis can be triggered in two principal ways: by toxic chemicals or injury leading to damage of important cells, tissues and organs (Schulte- Hermann et al., 1995). Initiation of apoptosis can occur as a result of insults from multiple stimuli, including heat, toxins (drugs), reactive oxygen species (ROS), growth factor withdrawal, cytokines such as transforming growth factor- beta, loss of matrix attachment, glucocorticoid, nitric oxide, and exposure to huge amount of radiation (Thompson, 1995; Pollman et al., 1996). These insults functions in conjunction with other intrinsic factors that determine the cell's potential to undergo apoptosis (McConkey and Orrenius, 1991).

The process of apoptosis in the testes in context of male reproduction helps in elimination of abnormal

spermatozoa, thus maintaining the nursing capacity of the sertoli cells (Sinha and Swerdloff, 1999). However, high levels of ROS disrupt the inner and outer mitochondrial membranes, inducing the release of the cytochrome-C protein and activating the caspase cascade which ultimately results in the fragmentation of a cell's DNA (Wyllie, 1980; Green, 1998; Makker, 2009). Cellular necrosis is not induced by stimuli intrinsic to the cells as in programmed cell death, but by an abrupt environmental perturbation and departure from the normal physiological conditions (Martins, 1978).

Smoking may also promote to a greater extent, the risk of dementia via its effect on other medical conditions such as coronary disorders (Nilsson et al., 2006), and it may interact with other cardiovascular risk factors in a synergistic or additive manner (Luchsinger et al., 2005). It may also interact with genetic factors such as apolipoprotein E genotype (APOE) to increase the risk of dementia (Beeri et al., 2006). Smoking cessation is associated with reduced risk of lung cancer (Godtfredsen, 2005), cardiovascular risk (Serrano et al., 2003), and cancer (Castellsague et al., 2000).

In this study, smoke extract of *D. stramonium* leaf may have acted indirectly through generation of high levels of ROS or directly as toxin to the cells of the liver and testes, affecting their cellular integrity and causing defect in membrane permeability. In cellular necrosis, the rate of progression depends on the severity of the insults. The greater the severity of the insults, the more rapid the progression of the injury. The principle holds true for



**Figure 10.** Photomicrograph of the testes of the animals in the control group (H&E x 480).

toxicological insult to the brain and other organs (Ito et al., 2003).

This investigation confirmed that smoking *D. stramonium* has toxic and disruptive interference on cellular integrity of the heart, liver, lungs, kidneys and testes of male Sprague Dawley rats. The heart, liver, lungs, kidneys and testes of the animals in the control group (A) showed better histological features (Figures 2, 8, 6, 4 and 10 respectively). There were no degenerative and/or disruptive changes, cellular hypertrophy in the sections obtained from the animals in the control group.

It was observed in this investigation that the exposure of male Sprague Dawley rats to the smoke extract of *D. stramonium* leaf have the potentials of causing damage to these vital organs.

## Conclusion

The effects of smoking on human health are serious and in many cases, deadly. Smoking is associated with higher levels of chronic inflammation. Data obtained from this study show that exposure to the smoke extract of *D. stramonium* leaf on the heart, liver, lungs, kidneys and testes have deleterious effects on the cytoarchitecture of these organs in male Sprague Dawley rats. Considering some of the effects of the smoke extract of *D. stramonium* leaf on the cellular components of the heart, liver, lungs, kidneys and testes in male Sprague Dawley rats, indiscriminate use of the plant should be discouraged, considering the negative impact it conferred on the studied organs in the treated animals in this investigation.

## ACKNOWLEDGEMENTS

Authors are deeply grateful to Professor E. A. Caxton-Martins (*FASM*) of the Department of Anatomy (Postgraduate Unit), University of Ilorin, Ilorin, Kwara State, Nigeria for research guidance and inspiration. We are thankful to Mr. Mohammed Abdulrasheed Ola of the Histopathology Department of the University of Ilorin Teaching Hospital, Ilorin, Kwara State, Nigeria for tissue processing and to Mr. Adekilekun A.M of the School of Basic Midwifery, University of Ilorin Teaching Hospital, Ilorin for providing the Kodak Digital Camera (Kodak Easyshare C183) used for taking the photomicrographs.

## REFERENCES

- Abena AA, Miguel LM, Mouanga A , Honde A T (2003). Evaluation of analgesic effect of *Datura fastuosa* leaves and seed extracts. *Fitoterapia*, pp. 486-488.
- Adekomi DA (2010). Madagascar periwinkle (*Catharanthus roseus*) Enhances Kidneys and Liver Functions in Wistar Rats. *International J. Biomed. Health Sci.*, 6(4): 245-254.
- Al-Hazmi E, Shakar S, Al-Sagaff S, Khoraiem S (2005). Histological changes of testis in mice after administration of doxorubicin HCL (Adriabastina), cytotoxic drug. Proceedings of 2nd Saudi Science Conference, Faculty of Science, KAU, Part 1, pp. 99-117.
- Anozie VC (1986). Pharmacognostic Studies on *Datura metel* Linn. Macro- morphology and micro-morphology of fruits and seed: *Herba Polonica*, 32(3/4): 197-208.
- Arouko H, Matray M D, Braganca C, Mpaka JP (2003). Voluntary poisoning by ingestion of *Datura stramonium*. Another cause of hospitalization in youth seeking strong sensation. *Ann. Med. Interne*, pp. 46-50
- Baylor P, Williams K (1999). Interstitial Nephritis, Thrombocytopenia, Hepatitis and Elevated Serum Amylase Levels in Patient receiving *Clarithromycin* Therapy. *Clin. Infect. Dis.*, 29: 1350-1351.
- Beerl MS, Rapp M, Silverman JM (2006). Coronary artery disease is associated with Alzheimer disease neuropathology in APOE4 carriers. *Neurology*, 66: 1399-1404.
- Berne R, Levy M (1998). *Physiology*. New York: C. V. Mosby Co.
- Binkley S (1995). *Endocrinology*. New York: Harper Collins College Publishers, pp.??
- Bose S, Sinha SP (1994). Modulation of Ochratoxin- produced Genotoxicity in Mice by Vitamin C. *Food Chem. Toxicol.*, 32: 533-537.
- Caroline J, Gross MS, Dian-Naire S (2003). Fiber Digestion in Mammals. *Pak. J. Biol. Sci.*, 6(17): 1564-1573.
- Castellsague X, Munoz N, De Stefani E, (2000). Smoking and drinking cessation and risk of esophageal cancer (Spain). *Cancer Causes and Control*, 11: 813-818.
- Chang C, Wang Y, Yang A, Chiang S (2001). Rapidly Progressive Interstitial Renal Fibrosis Associated with Chinese Herbal Medications. *Am. J. Nephrol.*, 21: 441-448.
- Checke P, Shull L (1985). *Natural toxicants in feeds and poisonous plants*. Westport: AVI Publishing Company.
- Clermont Y (1972). Kinetics of spermatogenesis in mammals: seminiferous epithelium cycle and spermatogonia renewal. *Physiol. Rev.*, 52: 198-235.
- Cohen JJ (1993). Apoptosis. *Immunol. Today*, 14: 126-130.
- Costanzo L (1998). *Physiology*. Philadelphia: W. B. Saunders Co.
- Dagher A, Bleicher C, Aston JA, Gunn RN, Clarke PB, Cumming P (2001). Reduced dopamine D1 receptor binding in the ventral striatum of cigarette smokers. *Synapse*, 42(1): 48-53.
- Di Chiara G, Acquas E, Carboni E (1992). Drug Motivation and abuse: A neurobiological perspective. *Ann NY Acad Sci.*, 654: 207-219.
- Disbrey BD, Rack JH (1970); *Histological Laboratory Methods*. Livingstone, Edinburgh, ISBN: 0443006946, pp. 56-128.

- Drury RAB, Wallington EA (1967). Carleton's Histological Technique. 4th Edn, Oxford University Press, London, pp. 120-123.
- Duez P, Chamart S, Hanocq J, Molle L, Vanhaelen M, Vanhalen F (1985). Comparison between thin chromatography, densitometry and HPLC for the determination of hyoscyamine and hyoscyne in leaves, fruits and seeds of *Datura* species. *Chromatography*, 329: 501-510.
- Duke J (1985). *CRC Handbook of medicinal herbs*. Boca Raton: CRC Press, Inc.
- Duke J (1992a). *Handbook of Phytochemical Constituents of GRAS Herbs and other Economic Plants*. Boca Raton: CRC Press.
- Duke J (1992b). *Handbook of biologically active phytochemicals and their activities*. Boca Raton: CRC Press.
- Fored C, Ejerblad E, Lindblad P, Fryczek J, Dickman P, Signorello L, Lipworth L, Elinder C, Blot W, McLaughlin J, Zack M, Nyren O (2001). *Acetaminophen, Aspirin and Chronic Renal Failure*. *N. Engl. J. Med.*, 345: 1801-1808.
- Friedman M, Levin C (1989). *Composition of Jimson weed (Datura stramonium) Seeds*. *Agric. Food Chem.*, 37: 998-1005.
- Ganong W (1999). *Review of medical physiology*. Stamford: Appleton and Lange.
- Gidado A, Bashirat JY, Gana GM, Ambi AA, Milala MA, Zanna H (2001). Effects of aqueous extracts of the seeds of *Datura stramonium* on some indices of liver and Kidneys function in rats. *Nig. J. Exptl. Appl. Biol.*, 2: 123-127.
- Godtfredsen NS, Prescott E, Osler M (2005). Effect of smoking reduction on lung cancer risk. *JAMA*, 294: 1505-1510.
- Green DR (1998). Apoptotic Pathways: The Roads to Ruin. *Cell*, 94: 695-698.
- Griffin J, Ojeda S (1996). *Textbook of endocrine physiology*. Oxford: Oxford University Press Inc.
- Grunewald S, Paasch U, Said TM, Sharma RK, Glander HJ, Agarwal A (2005). Caspase activation in Human Spermatozoa in Response to Physiological and Pathological Stimuli. *Fertil. Steril.*, 83(Suppl 1): 1106-1112.
- Guharov SR, Barajas M (1991). Intense stimulant effect: atropine intoxication from the ingestion and smoking of Jimson weed (*Datura stramonium*). *Vet. Toxicol.*, 33: 588-589
- Hasan SS, Kushwaha AK (1987). Chronic Effect of *Datura* (seed) Extract on the Brain of Albino Rats. *Jpn. J. Pharmacol.*, 44: 1-6
- Haschek W, Rousseaux C (1998). *Fundamentals of Toxicological Pathology*. London: Academic Press.
- Heath JW, Young B, Burkitt HG (1999). Circulatory system. In Young B, Heath JW (ed.): *Wheater's Functional Histology*, 3rd Edn. Churchill Livingstone, Edinburgh, pp. 140-145.
- Heller CH, Clermont Y (1964). Kinetics of the germinal epithelium in man. *Recent Progress in Hormone Research*, 20: 545-575.
- Hilscher W (1964). Beitrage zur orthologic und pathologies des "spermatogenesis" der ratte. *Beitr Pathol. Anatomy*, 130: 69-132.
- Holland E, Degruy F (1997). Drug-induced Disorders. *Am. Fam. Phys.*, 56, 1781-1792.
- Hussein K (1985). *Medicinal Plants in Libya*. Tripoli: Arab Encyclopedia House.
- Ito U, Sparts M, Walker JR, Warzo I (2003). Experimental cerebral ischemia in magolian gerbils (1), light microscope observations. *Acta Neuropathol.*, USA, 32: 209-223.
- Junqueira L, Carneiro J, Kelley R (1998). *Basic histology*. Stamford: Appleton and Lange.
- Junqueira LC, Carneiro J (2003). *Basic Histology*, 10th Edn, Lange Edition, McGraw Hill, 16: 340. ISBN 0-07-121565-4.
- Lesson T, Lesson C, Paparo A (1988). *Text / Atlas of Histology*. London: W. B. Saunders Co.
- Lord G, Tagore R, Cook T, Gower P, Pusey C (1999). Nephropathy Caused by Chinese Herbs in the UK. *Lancet*, 354: 481-482.
- Luchsinger JA, Reitz C, Honig LS (2005). Aggregation of vascular risk factors and risk of incident Alzheimer disease. *Neurology*, 65: 545-551.
- Mackinnon B, Boulton-Jones M, McLaughlin K (2003). Analgesic-associated Nephropathy in the West of Scotland: A 12-year Observational Study. *Nephrol. Dialysis Transplantat.*, 18: 1800-1805.
- Makker K, Agarwal A, Sharma R (2009). Oxidative Stress and Male Infertility. *Ind. J. Med. Res.*, 129: 357-367.
- Martins LJ, Al-Abdulla NA, Kirsh JR, Sieber FE, Portera-Cailliau C (1978). Neurodegeneration in Excitotoxicity, Global Cerebral Ischaemia and Target Deprivation: A perspective on the contributions of apoptosis and necrosis. *Brain Res. Bull.*, 46(4): 281-309.
- McConkey DJ, Orrenius S (1991). In Apoptosis: The Molecular Basis of Cell Death (Tome LD and Cope FO, eds), Cold Spring Harbor Laboratory Press, pp. 227-246.
- McIntyre M (1998). Chinese Herbs: Risk, Side Effects and Poisoning: The Case for Objective Reporting and Analysis Reveals Serious Misrepresentation. *J. Altern. Complementary Med.*, 4, 15-16.
- Monsees TK, Franz M, Gebhardt S, Winterstein U, Schill WB, Hyatpour J (2000). Sertoli cell as a target for reproductive hazards. *Andrologia*, 32: 239-246.
- Monsees TK, Hinkel S, Mihm K, Endo F, Schill WB, Hyatpour J (2001). Effects of environmental hormones on the functions of the testicular cells. *Proceedings of the 2nd status-seminar "Endocrine disruptors"* Berlin 2001, Um Welt Bundesamt, Berlin, pp. 133-136.
- National Institutes of Health Guide for the Care and Use of Laboratory Animals: DHEW Publication (NIH), revised. Office of Science and Health Reports, DRR/NIH, Bethesda, USA, 1985
- Nilsson PM, Nilsson JA, Berglund G (2006). Population-attributable risk of coronary heart disease risk factors during long-term follow-up: The Malmo Preventive Project. *J. Intern. Med.*, 260: 134-141
- Onarlioglu B, Onarlioglu T, Erdal S (1999). The Effect of Lead Inhalation on Rat Lung Morphology. *Tr. J. Med. Sci.*, 29: 617-622.
- Ono T, Eri M, Honda G, Kuwahara T (1998). Valvular Heart Disease and Chinese-herb Nephropathy. *Lancet*, 351: 991-992.
- Papadakis VE, Vlachopapadopoulou K, Syckle K, Tan C, Sklar C (1999). Gonadal function in young patients successfully treated for Hodgkin disease. *J. Pediatr. Oncol.*, 32(5): 366-372.
- Pfaus JG, (1990). Sexual behavior enhances central dopamine transmission in the male rat. *Brain Res.*, 430: 345-348
- Piva G, Piva A (1995). Anti-nutritional factors of *Datura* in Feedstuffs. *Plant toxin*, 4: 238-241
- Pla A, Alonso E, Batista-Viera F, Franco L (2003). Screening for Carbohydrate-binding Proteins in Extracts of Uruguayan Plants. *Braz. J. Med. Biol. Res.*, 36: 851-860.
- Pollman MJ, Yamada T, Horiuchi M, Gibbons GH (1996); Vasoactive Substances Regulate Vascular Smooth Muscle Cell Apoptosis. *Circ. Res.*, 79: 748-756.
- Reginster F, Jadoul M, Van Ypersele De Strihou C (1997). Chinese Herbs Nephropathy Presentation, Natural History and Fate after Transplantation. *Nephrol. Dialysis Transplant.*, 12: 81-86.
- Ren-sheng X, Giazhen Z, Yuyuan X (1985). Drugs acting on the nervous system. *Ethnopharmacology*, 14: 223-253.
- Russel A, Hardin J, Grand L, Fraser A (1997). *Poisonous plants of North Carolina*. Charlotte: North Carolina State University.
- Sakkas D, Mariethoz E, Manicardi G, Bizzaro D, Bianchi PG, Bianchi U (1999). Origin of DNA Damage in Ejaculated Human Spermatozoa. *Rev. Reprod.*, 4: 31-7.
- Sapori PMH, Chatelain P, Vallier P, Saez JM (1986). *In vitro* interaction between Sertoli cells and steroidogenic cells. *Biochem. Biophys. Res. Commun.*, 134(2): 957-962.
- Schulman ML, Bolton LA (1998). *Datura* seed intoxication in two horses. *J. S. Afr. Vet. Assoc.*, 69: 27-9
- Schulte-Hermann R, Bursch W, Marian B, Grasl-Kraupp B (1999). Active Cell Death (Apoptosis) and Cellular Proliferation as Indicators of Exposure to Carcinogens. *IARC Sci. Publ. (Lyon)*, 146: 273-285.
- Serrano M, Madoz E, Ezpeleta I (2003). Smoking cessation and risk of myocardial reinfarction in coronary patients: A nested case-control study. (In Spanish). *Rev. Esp. Cardiol.*, 56: 445-451.
- Sharpe RM (1993). The Sertoli cell. LD Russel and MD Grisword (eds). Cache River Press, Florida, pp. 391-418.
- Shen HM, Dai J, Chia SE, Lim A, Ong CN (2002). Detection of Apoptotic Alterations in Sperm in Subfertile Patients and their Correlations with Sperm Quality. *J. Hum. Reprod.*, 17: 1266-1273.
- Sinha HAP, Swerdloff RS (1999). Hormonal and genetic control of germ cell apoptosis in the testis. *Rev. Reprod.*, 4: 38-47.
- Spielman H (1998). Reproduction and development. *Environ. Health Perspect.*, 106: 571-576.
- Stevens A, Lowe J (2005). *Human Histology*, 3rd Edn, Elsevier Mosby, 12: 232. ISBN 0-3230-3663-5
- Thompson CB (1995). Apoptosis in the Pathogenesis and Treatment of



- Disease. *Science*, 267: 1456-1462.
- US Department Health Human Services. The Health Consequences of Smoking: A Report of the Surgeon General. U.S. Department of Health and Human Services, Centers for Disease Control and Prevention, National Center for Chronic Disease Prevention and Health Promotion, Office on Smoking and Health, 2004.
- Vaux DL, Haecker G, Strasser A (1994). An Evolutionary Perspective on Apoptosis. *Cell*, 76: 777-781.
- Webster D, Webster M (1974). *Comparative Vertebrate Morphology*. New York: Academic Press.
- Williams P, Rayson G (2003). Simultaneous multi-element detection of metal ions bound to *Datura innoxia* material. *J. Hazard Mater.*, 99, 277-285.
- Wyllie AH (1980). Glucocorticoid-induced Thymocyte Apoptosis is Associated with Endogenous Endonuclease Activation. *Nature*, 284: 555-556.
- Xie EF, Yang ZC, Wang D, Fu Q, Wei JJ (1998). A Rat Model of Smoke Inhalation Injury. *Ann. Burns and Fire Disasters*, 11(2).
- Yakubu MT, Akanji MA, Oladiji AT, Olatinwo AO, Adesokan AA, Yakubu MO, Owoyele BV, Sunmonu TO, Ajao MS (2008); Effect of *Cnidocolous aconitifolius* (Miller) I.M. Johnston leaf extract on reproductive hormones of female rats. *Iranian J. Reprod. Med.*, 6(3): 149-155
- Zargari A (1989). *Medicinal Plants*. 1st ed. Tehran University Press, pp. 637-639.