

Full Length Research Paper

Multi- Benefits of CAD/CAM Acrylic Bridge for Primary Incisors

Baydaa Ali Othman Al-Rawi, BDS, MSc, PhD,

Assistant Professor, Pediatric Dentistry, College of Dentistry, Ibn Sina University of Medical and Pharmaceutical Sciences, Iraq.

E-mail: baydaa.alrawi@yahoo.com , baydaa.alrawai@ibnsina.edu.iq

Accepted 23 October, 2022

Children with missing teeth have problems with self-esteem that can be improved through aesthetic dentistry and the dentists need to replace these teeth with an aesthetic maintainer. The aim of the present study was to evaluate the effectiveness of using CAD/CAM acrylic cantilever bridge to restore carious maxillary primary incisor and replacing prematurely lost adjacent incisor of pediatric patients. Twenty healthy children aged 2 – 4 years old of both gender, with prematurely lost one of the maxillary incisors before no more than one month and the adjacent incisor was carious were involved in this study. CAD/CAM acrylic cantilever bridge to restore carious maxillary primary incisor and replacing prematurely lost adjacent incisor of pediatric patients. No fracture of any cases was recorded. The gingival health around the acrylic bridge was showed mild inflammation characterized by a slight reddening of the tissue in 2, 0 and 1 of 20 cases at 3, 6 and 12 months, respectively. Significant higher parental satisfactions were received with progression of time. The fixed acrylic bridge seems to be successful in replacing missing anterior teeth and restoring carious one. It's satisfied by parents.

Keywords: CAD/CAM, Primary, Incisor, Space, Acrylic.

INTRODUCTION

Successful management of dental caries of pediatric patient considered being challenges, including access to care, behavior management and the need for sufficient effective treatment until tooth exfoliation (U.S. Public Health Service, 2000). However, Kapur et al. in 2005, reported that aesthetic rehabilitation of the primary dentition had a psychological benefit as well as functional benefit (Kapur et al., 2005).

Premature loss of teeth due to trauma or dental caries is a common occurrence in children. In case of premature tooth loss in anterior incisal segment there will result in minimum space loss and a linguodistal inclination of the teeth that causing a collapse of the anterior lingually and

shift of midline (Tandon, 2008). Also may lead to parafunctional habits as well as altered behaviour including depression with poor friend circle and non-acceptable daily life style (Da Silva et al., 2009). Mahmoud (2009) identified the negative effects of anterior tooth loss on patient's quality of life and there will be reduced confidence level among patients not having anterior teeth (AL-Omiri et al., 2009).

The aim of the present study was to evaluate the effectiveness of using CAD/CAM acrylic cantilever bridge to restore carious maxillary primary incisor and replacing prematurely lost adjacent incisor of pediatric patients. Clinical follow ups carried out after 3, 6 and 12 months.

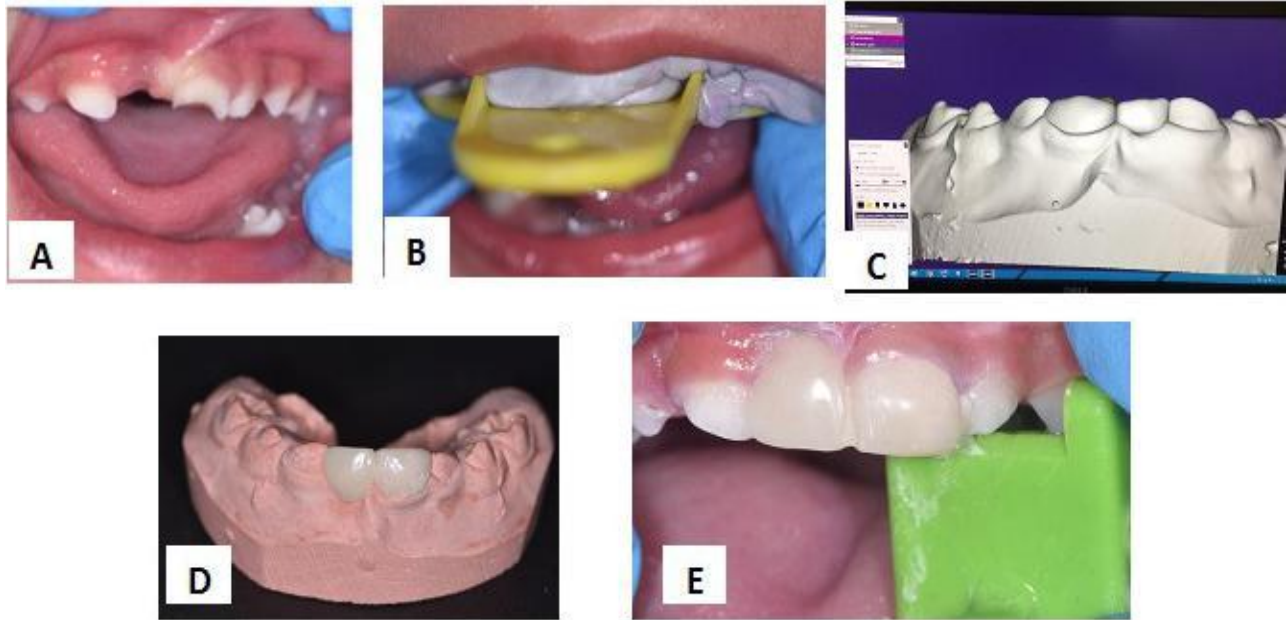


Figure 1. (A) Preoperative image demonstrate the edentulous area of prematurely loss maxillary right primary central incisor and carious maxillary left primary central incisor. (B) Impression taking for maxillary arch (C) Bridge designed by Exocad program, (D) the Final zirconium bridge in working cast. (E) cementation of aesthetic acrylic bridge.

MATERIAL AND METHODS

Twenty healthy children aged 2 – 4 years old of both gender, with prematurely lost one of the maxillary incisors before no more than one month and the adjacent incisor was carious were involved in this study. Full detailed treatment plans were explained to the children's parents and written consents were obtained for including the children in this study. Instructions on oral hygiene and appliance maintenance were given to the parents.

Constructions of fixed aesthetic acrylic bridge

Preoperative occlusal analysis was performed, then after impression was taken for maxillary arch using elastomeric impression material (ORMAMAX, Italy), working cast was performed. The shade color of the teeth was determined. The working cast 3D scanned using Activity 710 3D scanner (smart optics Sensortechnik GmbH, Germany). The design of the bridge carried out using Exocad Program (smart optics Sensortechnik GmbH, Germany). Acrylic block PMAA (Poly-methyl methacrylate) performed to the acrylic bridge using CAD/CAM machine (charlydental, Z.I. Fonlabour, France). After trimming, finishing and polishing of the bridge, the abutment tooth was isolated and air drying, the acrylic bridge was cemented with luting glass ionomer cement (RIVA, SDI, England) and occlusion checked for any premature contact (Figure 1).

The parents were advised to control their children to avoid chewing of hard food and to maintain proper oral hygiene. First recall of patient done after 24 hours

followed by recall visits every 3months. The patient was satisfied seeing the lost teeth back. The parent was informed that the appliance will be removed by a dentist at an age of approximately 6 years, to prevent interference of erupting permanent successors. The patient was also advised to return immediately in case there was any problem with the space maintainer, including distortion or breakage.

During follow up study, clinical examination include: fracture (0=no fracture, 1=small fracture, 2=bulk fracture), retention (1=good, 2=fair, 3=poor) and the condition of gingiva. A gingival score on a scale of 0 to 3 was determined: 0=no inflammation; 1=mild inflammation; 2=moderate inflammation; 3=marked inflammation (Loe and Silness, 1963).

Each child's parent was asked to provide feedback for evaluating their satisfaction with the restorations. Criteria used included: (1) appearance; (2) color match; (3) durability; (4) ability to eat and (5) feasibility of teeth brushing. Each of these criteria were scored using the following scale: 1=very dissatisfied; 2=dissatisfied; 3=neutral satisfied; 4=satisfied; 5=very satisfied (Roberts *et al.*, 2001) .

The data were summarized and described using relative frequencies and percentages for categorical variables. When the outcome variables were categorical, Chi-Square test was used to examine differences between frequencies and t- test was used to compare between means for statistical significance. Data were analyzed using SPSS software, version 16.0 (SPSS Inc., Chicago, IL, USA) for Windows. Statistical significance was set at $p \leq 0.05$.

Table 1. Demonstrated the clinical parameters at 3, 6 and 12 months recall visits.

Clinical Parameter	3 months	6 months	12 months	Chi-square test	p- value
	No. (%)	No. (%)	No. (%)		
Fracture	0 (0%)	0 (0%)	0 (0%)		
Appliance retention	3 (15 %)	0 (0%)	2 (10%)	0.00	1.00
Gingival inflammation	2 (10%)	0 (0%)	1 (5%)		

Table 2. Demonstrated the parents' satisfaction at 3, 6 and 12 months recall visits.

Parameters	3 months	6 months	12 months	t - test	p- value
	(Mean ± SD)	(Mean ± SD)	(Mean ± SD)		
Appearance	3.8 ± 0.1	4.4 ± 0.1	5.1 ± 0.1	3.45	0.00*
Color match	3.6 ± 0.1	4.1 ± 0.1	5.1 ± 0.1	3.77	0.00*
Durability	2.8 ± 0.3	3.3 ± 0.3	3.9 ± 0.3	4.27	0.00*
Ability to eat	3.0 ± 0.2	4.1 ± 0.2	4.9 ± 0.2	3.08	0.00*
Feasibility of teeth brushing	2.6 ± 0.2	3.5 ± 0.2	4.6 ± 0.2	2.99	0.00*

* Significant difference at $p \leq 0.05$.

RESULTS

Table (1) demonstrated the clinical parameters recorded at 3, 6 and 12 months follow up visit. Concerning the presence or not of any fracture, no fracture of any cases was recorded. Concerning retention of the acrylic bridges, 3, 0 and 2 of 20 cases showed poor retention that need recemented properly at 3, 6 and 12 months , respectively.

The gingival health around the acrylic bridge was showed mild inflammation characterized by a slight reddening of the tissue in 2, 0 and 1 of 20 cases at 3, 6 and 12 months, respectively. The differences not reach significant level at $p \leq 0.05$.

Table (2) showed the data from the parental satisfaction survey for appearance, color match, durability, ability to eat and feasibility of teeth brushing. The parental satisfactions were significantly recorded to be increased with progression of recall visits.

DISCUSSION

To the best of author' knowledge, this is the first known clinical study reporting the clinical longevity of using CAD/CAM fixed acrylic bridge for replacing prematurely loss primary maxillary incisor in young children in addition of restoring adjacent carious one. Even this type of space maintainer and / or aesthetic restoration is fixed, but the important point it will not restricted the growth because it was cantilever type of bridge. This study has its limitation, which is the sample size. This is understandable due to the cost of treatment. Aesthetic dental treatment in Iraq is not subsidized by the Iraqi Health System. This makes

the burden of the cost on the parents.

Concerning the presence or not of any fracture, no fracture was recorded because CAD/CAM acrylic bridge formed from only one type of material; Poly(methyl methacrylate, which is strong, tough, and lightweight material (Smith and Hashemi, 2006).

Concerning retention, the appliance showed high retention that's related to the properties of Riva luting glass ionomer cement used in cementation and it chemically bonds to metal substrates and the tooth. It has high flexural strength enhances longevity of a glass ionomer luting cement by withstanding mastication forces. Riva Luting's high flexural strength increases its durability in the oral environment and long term ability to retain indirect restorations. Also, Riva Luting has low solubility in the oral environment. This increases the material's ability to resist disintegration and wear caused by oral acidity (Manufacturer's Information, 2017).

The gingival health around the acrylic bridges showed mild inflammation than around the acrylic bridge. So, repeated instruction and information about good oral hygiene and diet control were given to the parents at each recall visits.

The means of parental satisfaction were significantly ($p \leq 0.05$) increased for appearance, color match, durability, ability to eat and feasibility of teeth brushing with progression of recall visits, these related to the advantages of fixed aesthetic CAD/CAM acrylic bridge which considered to be color stable with minimal bulkiness not cause food and plaque accumulation and easily to clean to maintain good oral hygiene and sufficient strength to withstand force of mastication in addition to the minimal chair-side dental work that reduce visits and time need the child set on dental chair.

CONCLUSION

Replacement of the missing incisors with fixed acrylic bridge appliance provides a reasonable treatment option for preschool children with prematurely loss primary incisor. In the present study, the simple technique in fabrication of the appliance allows it to be used in daily clinical practice with greater success both to the child and parent in establishing a positive attitude and satisfaction in relation to function and aesthetics in replacement of the missing anterior tooth and restoring adjacent carious one. So, the pediatric dentists should always search and develop the easier the more effective way to restore any defect in child teeth.

REFERENCES

- AL-Omiri MK, Karasneh JA, Lynch E, et al (2009). Impacts of missing upper anterior teeth on daily living. *Int. Dental. J.* 2013:127–132.
- Da Silva K, Roy B, Yoon RK (2012). Early loss of primary incisors due to para-functional tendency. *N Y State Dent J.* pp. 26–30.
- Kapur A, Chawla HS, Goyal A, Gaube K (2005). An esthetic point of view in very young children. *J. Clin. Pediatr. Dent.* 30(2):99–103.
- Loe N, Silness J (1963). Periodontal disease in pregnancy. Prevalence and severity. *Acta Odontol. Scand.* 21:553-551.
- Manufacturer's Information (2017). SDI Company, England. <http://www.sdi.com.au/au/product/riva-luting/>
- Roberts C, Lee JY, Wright JT (2001). Clinical evaluation of and parental satisfaction with resin-faced stainless steel crowns. *Pediatr. Dent.* 23:28-31.
- Smith WF, Hashemi J (2006). *Foundations of Materials Science and Engineering* (4th ed.). McGraw-Hill.
- Tandon S (2008). *Text book of pedodontics*. 2nd edn. Paras Medical Publisher. pp. 446–65
- U.S. Public Health Service, Office of the Surgeon General; National Institute of Dental and Craniofacial Research (2000). *Oral Health in America: A Report of the Surgeon General*. Rockville, Md.: Department of Health and Human Services, U.S. Public Health Service.