

Case Report

A rare presentation of hepatocellular carcinoma in a young adult: Case report

Erwa Elmakki

Department of Internal Medicine/Gastroenterology, Faculty of medicine, Jazan University, PO box 114, Jazan, Saudi Arabia Kingdom.

E-mail: erwamakki@gmail.com

Accepted 22 August, 2013

Hepatocellular carcinoma (HCC) is the most frequent type of liver malignancy. Most cases of HCC are secondary to either viral hepatitis (hepatitis B, C) or alcoholic cirrhosis, however liver cirrhosis due to any other causes is considered as a risk factor for development of HCC. HCC in a young patient with no cirrhosis or fibrosis is a relatively rare condition. The present case report describes a young male (24-year-old) patient who presented with a 2-months history of fever, right upper quadrant abdominal pain and weight loss with no evidence of pre-existing liver disease, initially treated as liver abscess, however his CT abdomen with intravenous contrast showed numerous heterogeneous hepatic hypodensities many with ring enhancement, serum alphafetoprotein level found to be very high (>1000ng/l) and histological studies confirmed the presence of HCC. The present case findings suggest that multifocal HCC can occur in a young patient without having an apparent risk factors and clinical presentation of HCC can be similar to liver abscess.

Keywords: Hepatocellular carcinoma, liver malignancy, hepatitis, liver abscess, liver cirrhosis.

INTRODUCTION

Hepatocellular carcinoma (HCC) is the most frequent type of malignant lesion of the liver. Liver cancer can rarely occur below the age of 40 years and reaches a peak at approximately 70 years. Rates of HCC among men are two to four times as high as the rates among women.¹ Although not frequently, HCC can occur in a non-cirrhotic liver. In comparison with cirrhotic HCC, non-cirrhotic HCC has some characteristics, such as: (a) a lower male preponderance and a bimodal age distribution; (b) a lower prevalence of the three major risk factors (hepatitis B and C virus infections and alcohol abuse), with an increased prevalence of other etiologies, such as exposure to genotoxic substances and sex hormones, inherited diseases, genetic mutations; (c) a more advanced tumor at the time of diagnosis, as it is usually detected due to the occurrence of cancer-related symptoms, outside any scheduled surveillance program.

CASE REPORT

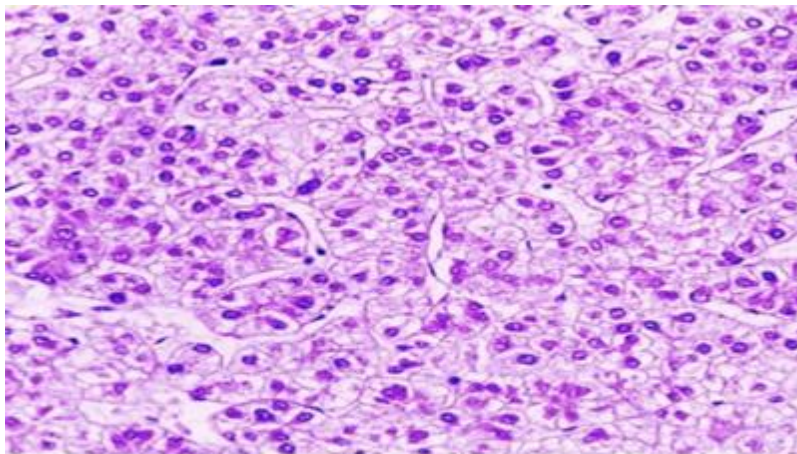
A 24-year-old patient was admitted to our hospital with a

2-month history of right hypochondrial pain and fever. Also he was said to have decreased appetite, occasional vomiting and marked loss of weight, but he had no recent change in bowel habits. His systemic review was unremarkable. He had no past medical history of significance, also no drug or family history of notice. He denied cigarette smoking or alcohol consumption. On examination he appeared sick, jaundiced and febrile, with body temperature of 38.5 °C. Abdominal examination revealed a palpable liver (10 cm below the right costal margin, irregular firm and tender), but no splenomegaly or ascites. He had no peripheral stigmata of chronic liver disease, neither signs of hepatic failure. Examination of other systems was normal. Before coming to our hospital he was seen in a peripheral hospital in which a diagnosis of liver abscess was initially made, so he was empirically given intravenous antibiotics consisting of Ceftriaxone and Metronidazole. However in our hospital abdominal ultrasonography reported multiple hypodense hepatic lesions with no ascites or evidence of portal hypertension.

Figure 1.

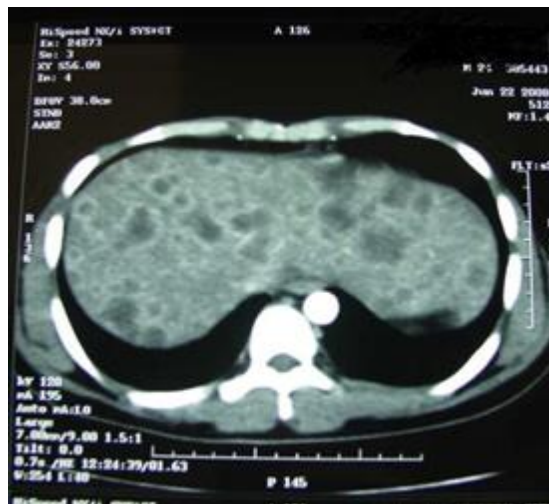

Figure 2.



CT abdomen with intravenous contrast showed multiple hypodense hepatic lesions with ring enhancement (Fig 1), serum alpha-fetoprotein found to be >1000ng/l, and histological studies of liver specimen reported malignant cells consistent with hepatocellular carcinoma (Fig 2). CBC revealed a Hb of 14.6gm/dl, WBC of 11300/ cmm, and platelets of 291,000/cmm, LFTs showed total bilirubin of 35 mmol/l (reference range 0-17), ALT 54 iu/l (30-65), AST 74 u/l (15-37), alkaline phosphatase 344u/l (50-136), GGT 646 u/l(1-94), total protein 64g/l (64-82), albumin 33 g/l (34-50), PT and PTT were normal, serology for viral hepatitis including HBsAg, HBcAb, and HCV-Ab was negative, also PCR for HBV-DNA was negative, iron panel was normal, RFTs and electrolytes were normal except for hypercalcemia (serum Ca⁺⁺ of 3.32 mmol/l) but PTH and phosphate were normal. Septic workup showed no evidence of infection. Also metastatic workup including PSA and CEA levels, chest-x-ray, chest

CT scan, bone scan, upper and lower GI endoscopies all were normal. In our hospital he received only symptomatic treatment and we decided to refer him to a higher hepatology centre for further management, but he requested to go to his native country to receive treatment there.

DISCUSSION

Hepatocellular carcinoma (HCC) is the common type of primary liver cancer. HCC has an annual incidence of 600,000 newly diagnosed patients. Thus HCC constitutes the sixth most frequent form of cancer worldwide and it holds third place concerning malignancy related mortality. Eighty per cent (80%) of liver cancers are found in cirrhotic livers, which in themselves carry a high risk for HCC.³ HCC in a young patient with no cirrhosis or

fibrosis is a relatively rare diagnosis.⁴ This is compatible with our case as he showed no evidence of pre-existing liver disease. Clinical presentation in our patient was similar to liver abscess in view of fever, right hypochondrial pain and leukocytosis. Few similar cases of HCC mimicking liver abscess were reported by Yeometal and Hayashi etal.^{5,6} HCC in adults is largely a disease of 50-70 year old. However there is a type of HCC with characteristic histological features usually occurs in young adults known as fibrolamellar carcinoma (FHCC). FHCC is rich in fibrous tissue, males and females being at equal risk, it does not produce alpha-fetoprotein and it has a good prognosis.⁷ The age of our patient and lack of coexisting liver disease favor the diagnosis of FHCC, but the radiological and histological findings in addition to high alpha-fetoprotein level are against such diagnosis. Pathologically HCC can be either single or occur as multiple nodules throughout the liver. Histologically it consists of cells resembling hepatocytes. It can metastasize via the hepatic or portal veins to the lymph node, bones and lungs.⁸ In our patient the histopathological studies revealed malignant cells consistent with HCC. Hypercalcemia in our patient can be part of paraneoplastic manifestations of HCC. Our patient showed normal serum PTH and phosphorus levels (ruling out the possibility of primary hyperparathyroidism), also his metastatic workup showed no evidence of bone disease. Some cases of severe hypercalcemia associated with HCC were reported, in which the cause of hypercalcemia was ectopic PTH-related peptide secretion. This type of hypercalcemia usually responds to treatment of the underlying tumor.^{9,10}

HCC on CT scan may appear as focal lesion which can invade the portal or hepatic veins. It can also be multifocal or may be found diffusely in the liver. It usually has a heterogeneous appearance. On CT and MRI it typically enhances more than the adjacent liver after the intravenous contrast is administered especially if the liver is imaged within 20 seconds after contrast is given (during the hepatic arterial phase of contrast enhancement of the liver, since HCC is hypervascular cancer and is fed by hepatic artery).¹¹

Patients who are not candidate for liver transplantation or resection, tumor ablation can be applied to extend life and to potentially downstage the tumor to permit transplantation or resection. Alternatively, patients who have advanced malignancy may benefit from palliative therapy. The most commonly offered therapy is transcatheter arterial chemoembolization (TACE).¹² Finally the most interesting features in our case are the way in which it presented and the age in which it occurred.

CONCLUSION

Although HCC is common worldwide especially in areas in which there is a high endemicity of viral hepatitis B and C, multifocal. HCC in young adults without clear risk factors is an extremely rare presentation.

REFERENCES

1. El-serag H. Hepatocellular carcinoma: review article. *N Eng J med* 2011, 365: 1118- 1127.
2. Trevisani F, Frigerio M, Santi V, Grignaschi A, Bernardi M. Hepatocellular carcinoma in non-cirrhotic liver: A reappraisal. *Digestive and liver disease* 2010, 42: 341-347.
3. Mauss S, Berg T, Rockstroh J, Sarrazin C, Wedemeyer H. Hepatocellular carcinoma, *Hepatology-a clinical text book*, 2nd edition. Germany: Flying publisher 2010, P 303-304
4. Thomas DB, Hall AB, Michel M. Non-cirrhotic hepatocellular carcinoma in a young Active duty male. *Mil Med*.2011,176:475-6.
5. Yeom JO, Yoon SB, Kim JG, Oh JH, Jeon EJ, Jeong et al. a case of hepatocellular carcinoma combined with Liver abscess. *korean J gastroenterol* 2009, 53:378-82.
6. Hayashi T, Honda H, Kaneko K, Fukuya T, Tateshi Y, Ro T. Hepatocellular carcinoma with pyrexia: Report of a case. *Radiat Med* 1995, 13: 133-6.
7. Terzis I, Haritanti A, Economou I. Fibrolamellar hepatocellular Carcinoma: a case report with distinct radiological features. *J gastrointestinal Cancer*, 2010, 41:2-5.
8. Parveen Kumar and Micheal Clark. Hepatocellular carcinoma. *Clinical Medicine*, 5th ed. Toronto: W. B Saunder 2002; p: 384.
9. Abe Y, Makiyama H, Fujita Y, Tachibana Y, Kamada G, Uebayashi M. Severe hypercalcemia associated with hepatocellular carcinoma secreting intact parathyroid hormone: a case report, *The Japanese Society of Internal Medicine* 2011,50:329-333.
10. MW Ghobrial, J Georg, S Mannam, SR Henien. Severe hypercalcemia as an initial presenting manifestation of hepatocellular carcinoma. *Canadian Journal of gastroenterology* 2002, 9: 607-609.
11. Douglas S, Kevin R., Stuart A, Liver disease. *Radiology secrets*.1st edition. USA: Amazon.com 1998, P132.
12. Cormier JN, Thomas KT, Chari RS, et al. Management of hepatocellular carcinoma. *J Gastrointest Surg*. May 2006;10(5):761-80.