

Short Communication

Cardiothoracic ratio of non - hypertensive patients at Jos University teaching hospital (JUTH)

A Shugaba^{1*}, M Umar¹, A Asunugwo¹, C. Uzokwe¹, A Rabi², R Matthew³ and S Mohammed⁴

¹Department of Human Anatomy, University of Jos, Jos, Plateau State, Nigeria.

²Department of Human Physiology, University of Jos, Jos, Plateau State, Nigeria.

³Pathfinder International, Asokoro, Abuja, Nigeria.

⁴Department of Radiology, Maitama General Hospital, Abuja, Nigeria.

Accepted 17 October, 2022

Radiography of the heart and great vessels is the commonest examination performed as routine investigation of cardiovascular system; it identifies abnormalities associated with the size, shape and contours of the heart. The aim of the study is to determine the mean cardiothoracic ratio among non-hypertensive patients at Jos university teaching hospital (JUTH). A retrospective assessment of 126 chest radiographs of non- hypertensive patients performed at radiology unit of university of Jos teaching hospital from June 2009 to July 2010 using the simple random sampling method. Of the 126 subjects 73 were males and 53 were females within an age range of 18- 86years. The mean cardiothoracic ratio (C.T.R) was 0.462. From the study 126 patients (73 males and 53 females) had their CTR measured and there was no significant difference between the CTR of males and females $p > 0.115 > 0.05$. The mean heart diameter is 13.3849, mean thoracic diameter 28.9357 and mean CTR 0.4622

Keywords: Cardiothoracic ratio, non - hypertensive patients and Jos University teaching hospital (JUTH)

INTRODUCTION

Radiography of the heart and great vessels is the commonest examination performed as routine investigation of cardiovascular system; it identifies abnormalities associated with the size, shape and contours of the heart. Accelerated hypertension is associated with headache, drowsiness, confusion, vision disorder, nausea and vomiting, symptoms which are collectively referred to as hypertensive encephalopathy (Adefila, 2008). The routine has been the conventional erect postero-anterior (PA) projection of the chest on full arrested inspiration at pre-set focus film distance (FFD)

using appropriate exposure (Adefila, 2008).

Cardio thoracic ratio is the transverse diameter of the heart to the inner diameter of the rib cage at its widest point as determined on a chest radiograph. The cardiothoracic ratio is the fraction derived by measuring the distance from the midline to the most lateral aspect of the left and right heart borders (left apical and right atrial silhouettes, respectively) and dividing that sum by the maximum horizontal measurement of the thorax, from left pleural surface to right pleural surface (generally taken at the level of the diaphragmatic apices) on a poster anterior chest radiograph (CXR). The determination of CTR can be performed and reproduced rapidly and with considerable precision, even without aid of a ruler or other measuring device. Therefore, since first described

*Corresponding author E-mail: alishugaba@yahoo.com

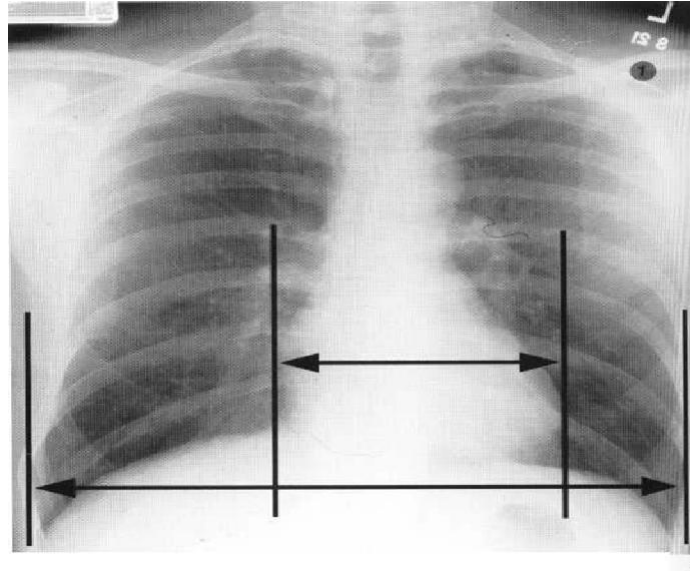


Figure 1.0. Diagram showing cardiothoracic ratio measurement

Table 1. Descriptive statistics: showing mean, standard deviation, minimum and maximum values of cardiac diameter, thoracic diameter and cardiothoracic ratio of the study population

Status		Heart diameter	Thoracic diameter	CTR
Non hypertensive	Mean	13.3849	28.9357	0.4622
	N	126	126	126
	Std. Deviation	1.74695	2.90334	0.03283
	Minimum	9.7	23.5	0.36
	Maximum	17.5	35.8	0.5

by Danzer in 1919, it has been a widely followed.

Cardiothoracic ratio was obtained from postero-anterior chest radiographs of non- hypertensive patients.

MATERIALS AND METHODS

A non-experimental retrospective research design was employed in this study. Secondary data was obtained from the radiology unit of the university of Jos teaching hospital (JUTH) consisting of chest radiograph of non-hypertensive patients. The target population of this study consisted of all the chest radiographs of non-hypertensive patients produced in the radiology department (JUTH) from June 2010 - July 2010. Chest radiographs of non-hypertensive subjects produced in the radiology department JUTH from (Jun 2010-july2010) was used as the sampling frame. A total of 126 chest radiographs of non-hypertensive patients were used. This was determined using the Taylor's formula. The sampling technique used in this study was the simple random sampling method for it has the basic characteristics of all members of the population having equal and independent chance of being included in the study (Ndiyo et al., 2005). Subjects recruited were non-hypertensive patient who

had undergone chest x-ray at the radiology unit of university of Jos teaching hospital (JUTH) and were able to meet the following inclusion criteria; patients not diagnosed with hypertension, patients with no underlying cardiovascular clinical symptoms, patients aged 18 years and above. The following was used as an exclusion criteria; All subjects outside the inclusion criteria, technically unsatisfactory radiographs, like the inability to identify one or both cardiac borders (silhouette sign) or mediastinal shift and severe rotation, patients with thoracic or spinal deformity. Data was collected from non-hypertensive subjects. Cardiothoracic ratio (CTR) of each of the selected participants was measured with a ruler under optimal viewing condition.

RESULTS

Data obtained were analysed using statistical software (SPSS version 16). Inferential and descriptive statistics were used to analyse the data. The study consists of 126 non-hypertensive subjects and there were 73 males and 53 females, the mean cardiothoracic ratio (CTR) was 0.462.

DISCUSSION

Assessment of cardiac size by determining cardiothoracic ratio (CTR) is a rough quantitative measurement (Colleen et al., 2000) which can be influenced by factors such as thoracic cage abnormalities, obesity, and ventilation (Jitender, 2003), although the widely accepted upper limit is 50%, it may exceed in at least 10% of normal individuals but may be up to 60% in neonates which is due to relatively undeveloped lungs (Razari et al., 1995).

Furthermore, other radiographic techniques such as lateral and oblique projections of the chest are useful and can supplement the standard poster anterior projection (Razari et al., 1995) for enlargement of the cardiac silhouette alone is relatively non specific because the central dense shadows seen on poster anterior chest radiograph comprises of other structures apart from the heart (Peter and Mark, 2003).

In this study the mean cardiothoracic ratio (CTR) was 0.462. These values prove less than that of which reported a mean CTR of 0.45 (45%) and 0.46(46) among males and females respectively (Giwa, 2004), such difference could be associated to the technique of sampling and equipment used for data collection.

CONCLUSION

From the study 126 patients (73 males and 53 females) had their CTR measured and there was no significant difference between the CTR of males and females $p > 0.05$.

The mean heart diameter is 13.3849, mean thoracic diameter 28.9357 and mean CTR 0.4622

REFERENCES

- Adefila James (2008). Chest radiograph in the management of patients, Department of medical radiography, University of Maiduguri(unpublished)
- Colleen Sanders, Beningo Soto (2000). Chest roentgenology and fluoroscopy: Imaging in cardiovascular disease; Lippincott, Williams and Wilkins
- Giwa Aisha (2004). Measurement of heart size on postero anterior chest x-ray, Department of Human anatomy, university of Maiduguri
- Jitender P (2003). Chest and Cardiovascular imaging; Diagnostic Radiology 2 edition; jaypee Brothers medical publishers limited
- Ndiyo B, Jenkins A, Martins J (2005). Mitochondrial DNA and retroviral RNA analysis of archived oral polio vaccine (OPV CHAT) materials: evidence of macaque nuclear sequences confirms substate identity. *VACCINE* 23:1639-1648
- Peter W, Mark C (2003). The normal heart, anatomy and technique and examination, Textbook of radiology and imaging; Elsevier science limited. pp. 502-517
- Razari MK, Dake MD, Semba CP (1995). Percutaneous endoluminal placement of stentgraft for treatment of isolated iliac artery aneurysm *Radiol.* 197:801-804